

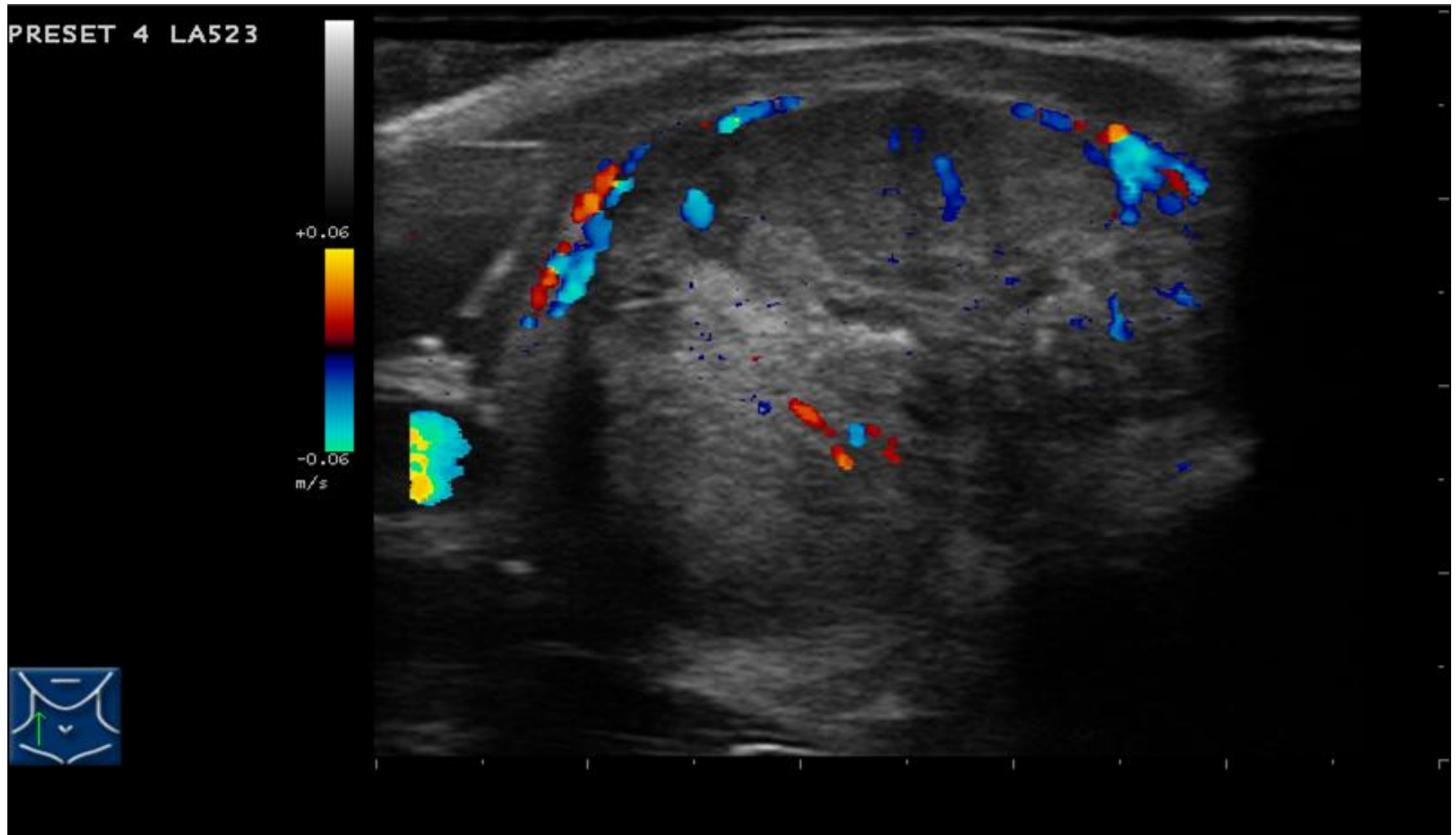
**Homme de 34 ans avec masse de la
thyroïde en croissance rapide.**



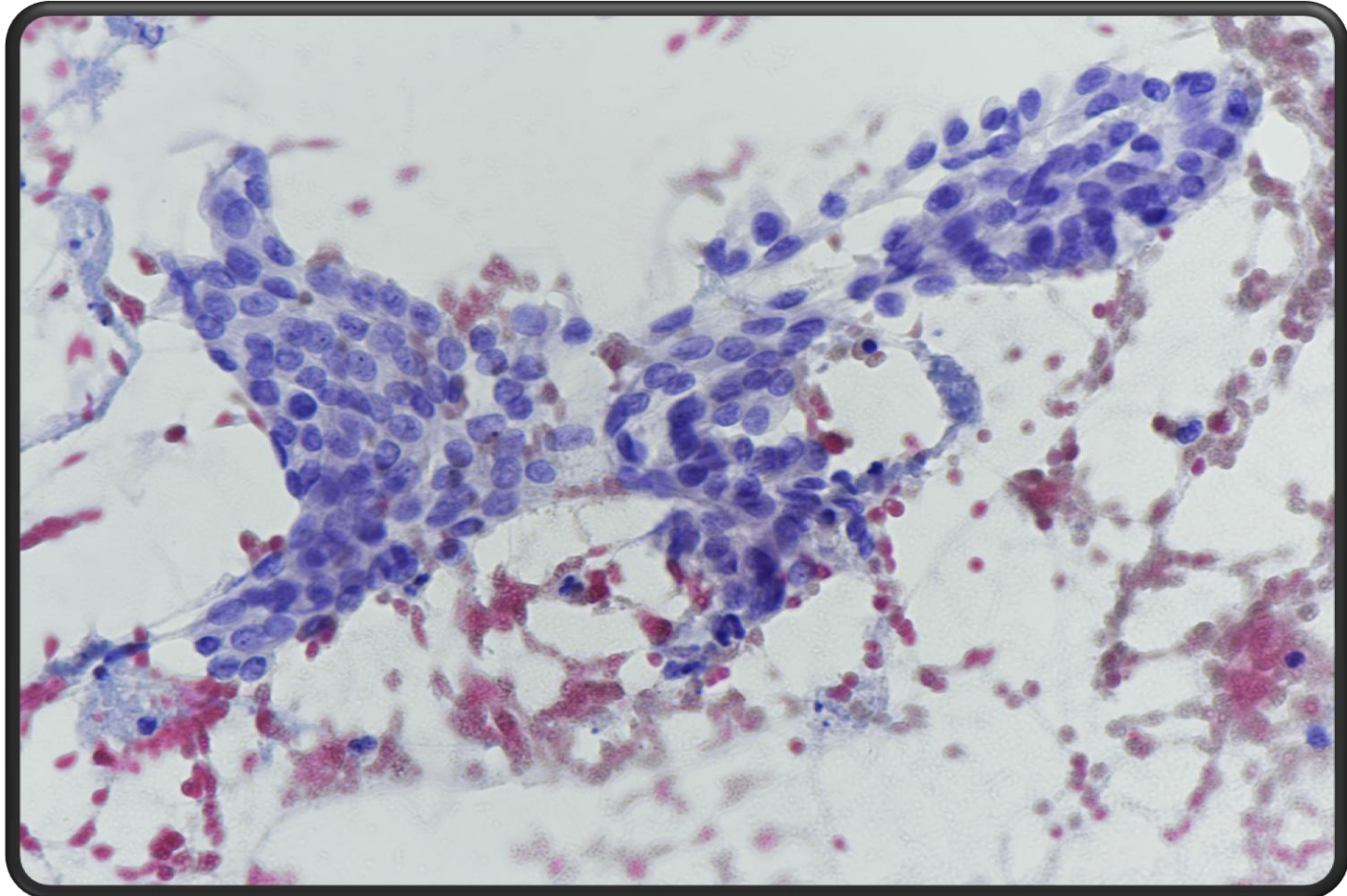
FNA de la thyroïde

Echographie du 04.08.2015

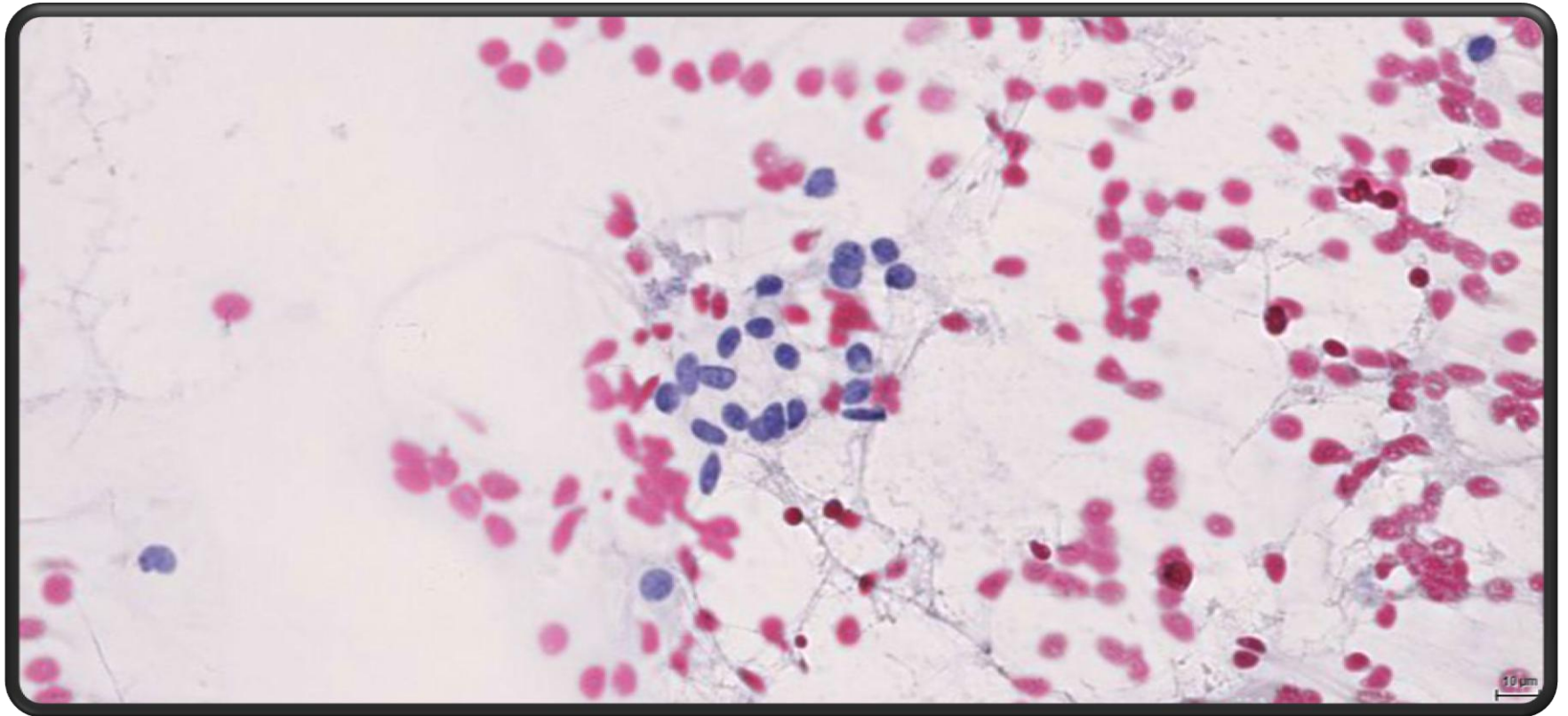
Nodule du lobe D avec vascularisation essentiellement périphérique,
vue longitudinale



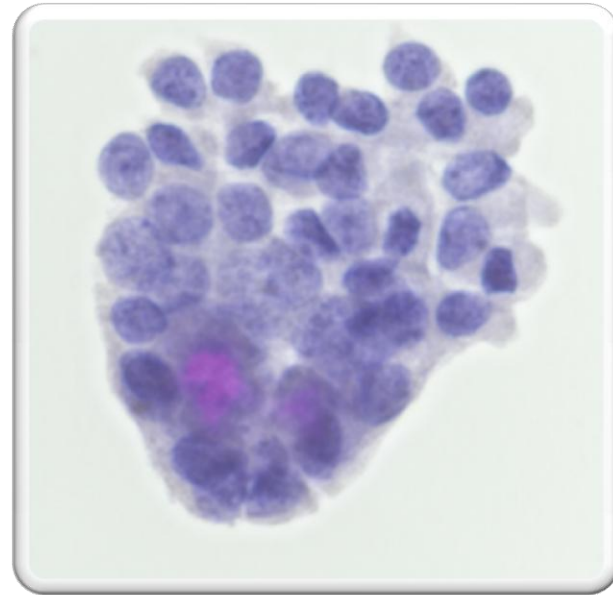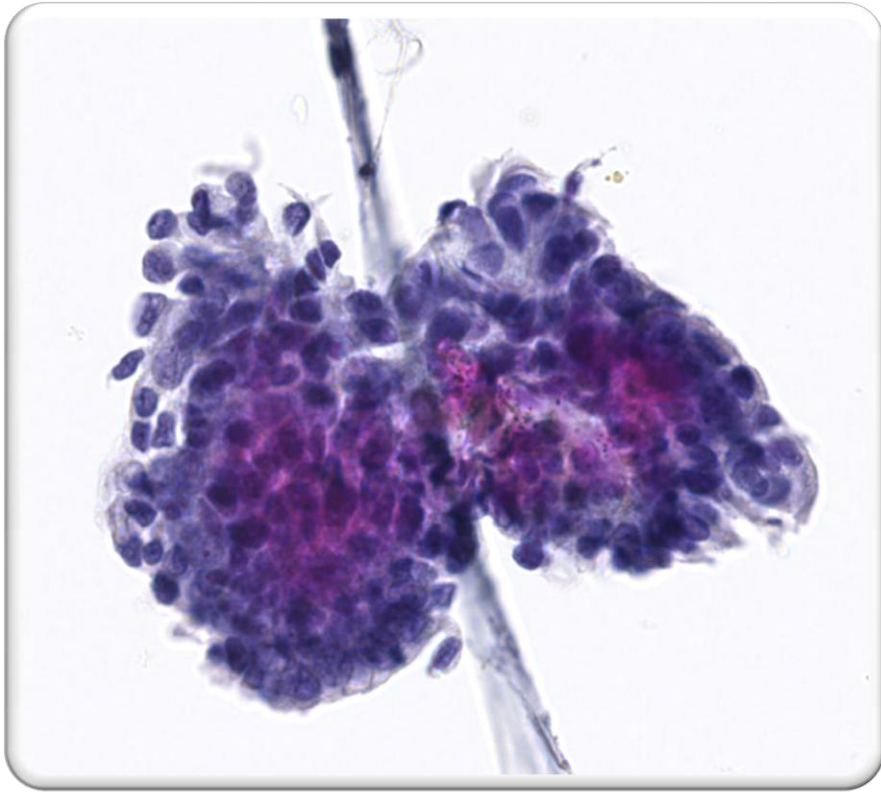
Pap, smear



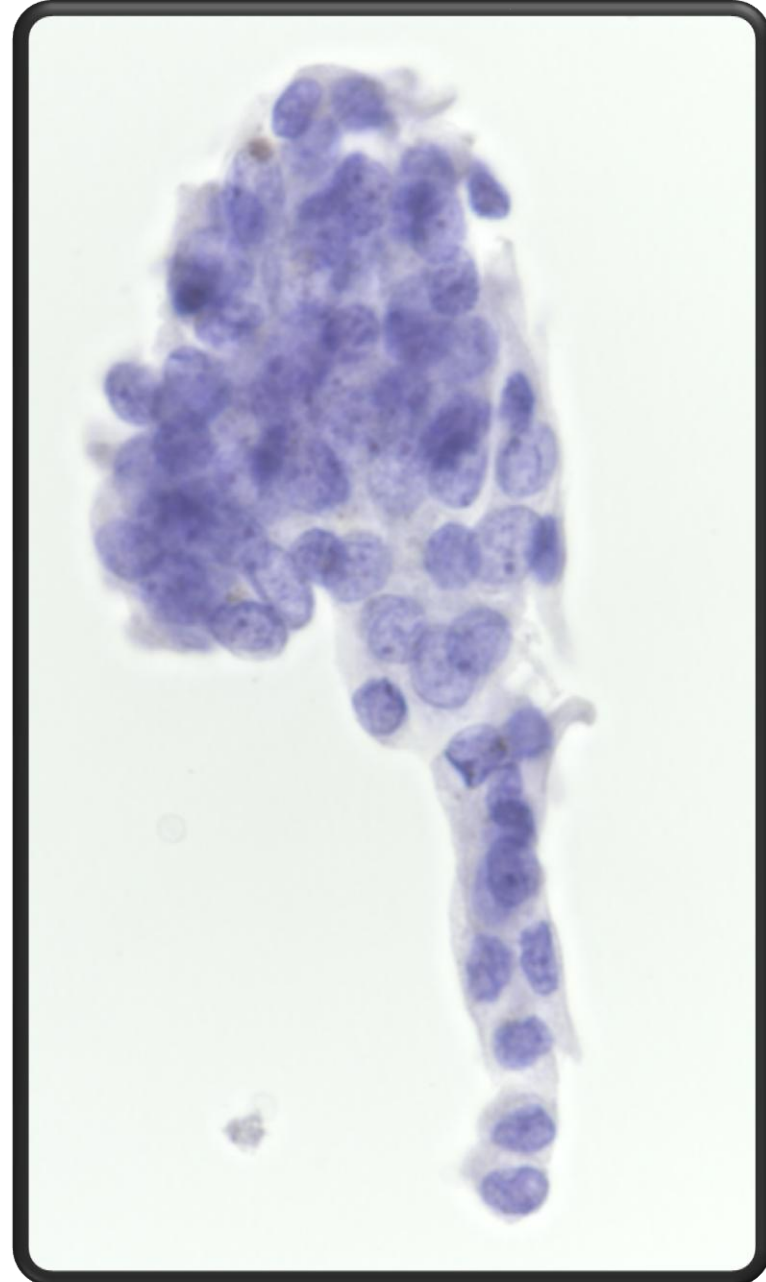
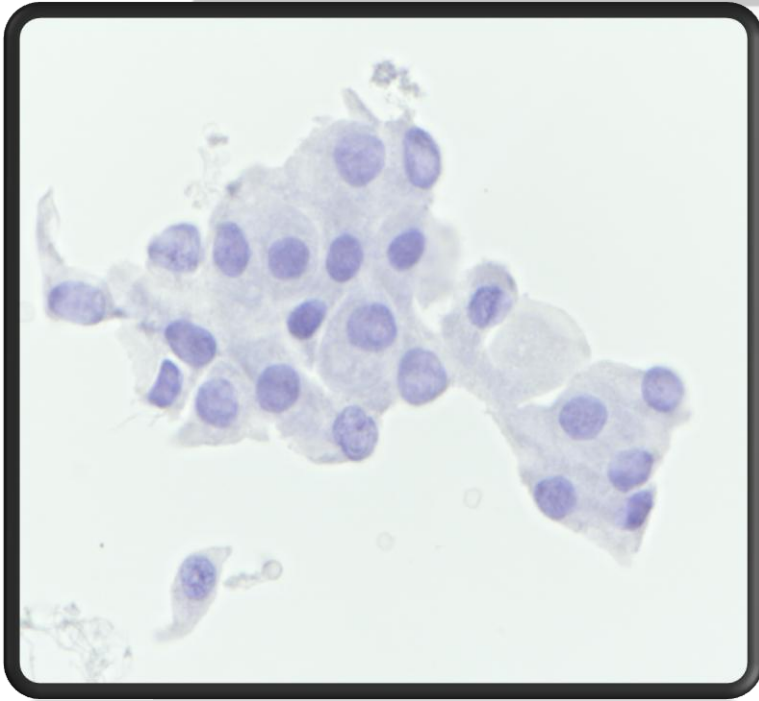
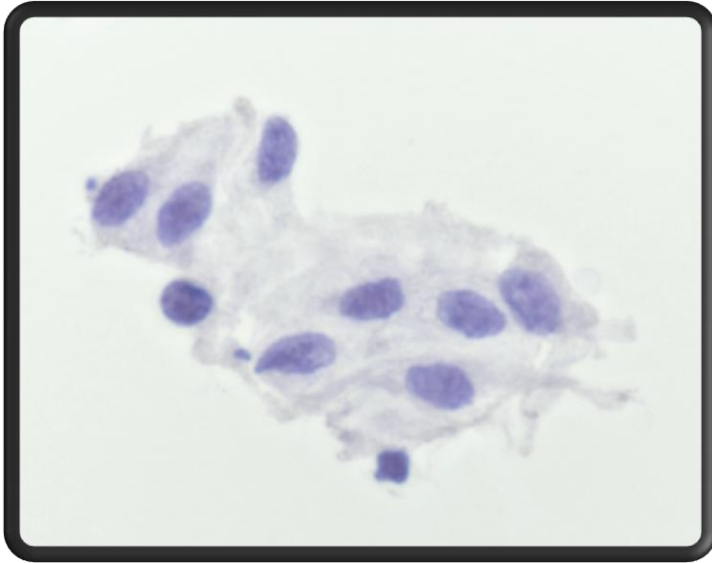
Pap, smear



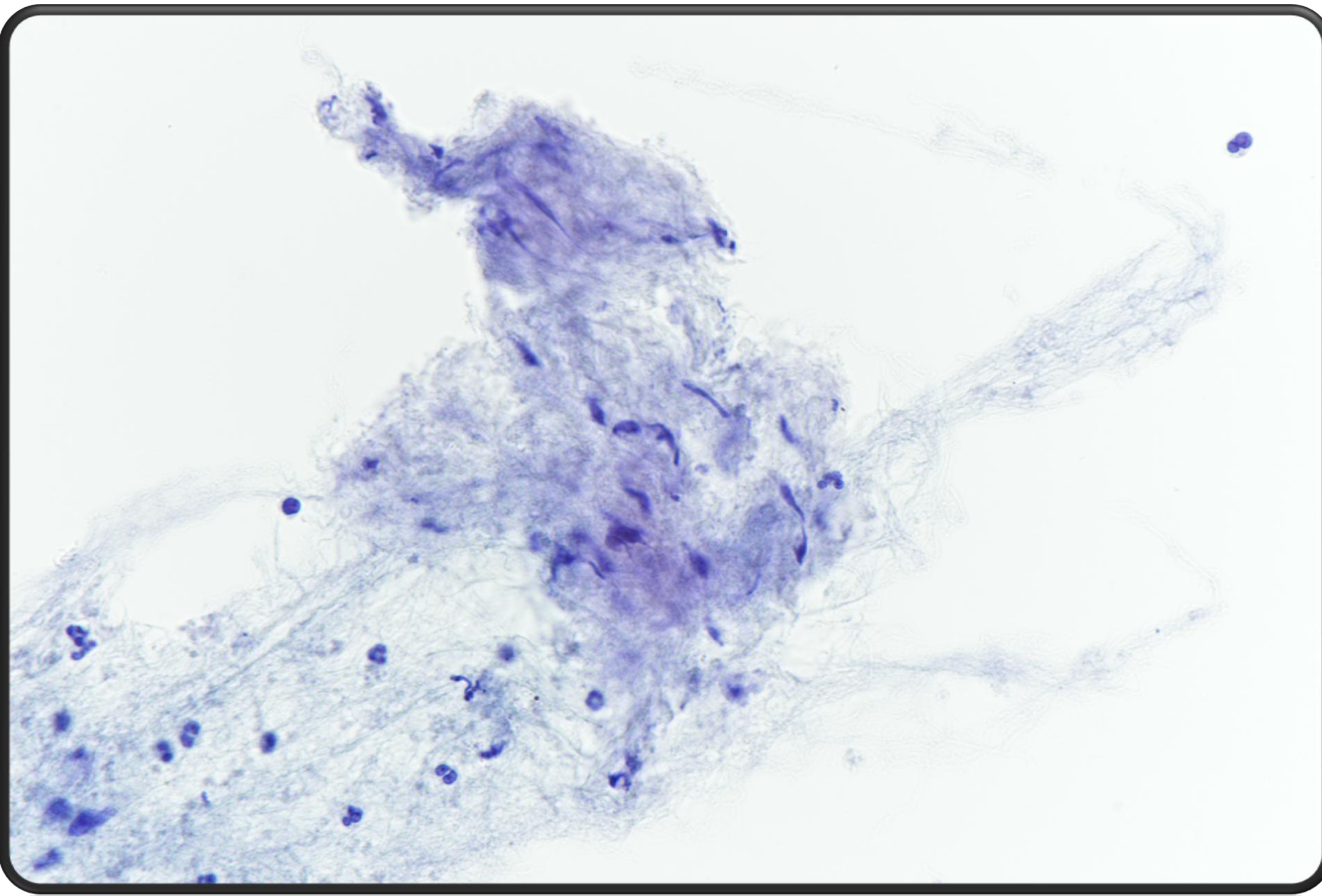
Pap, liquid-based cytology



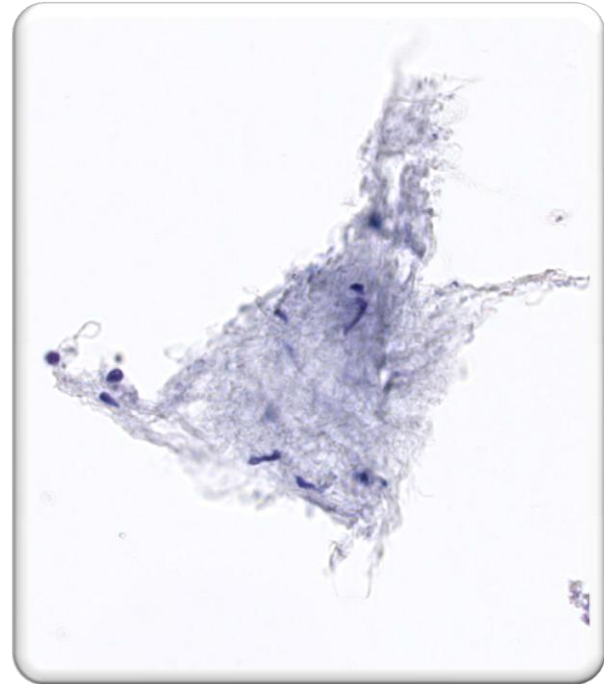
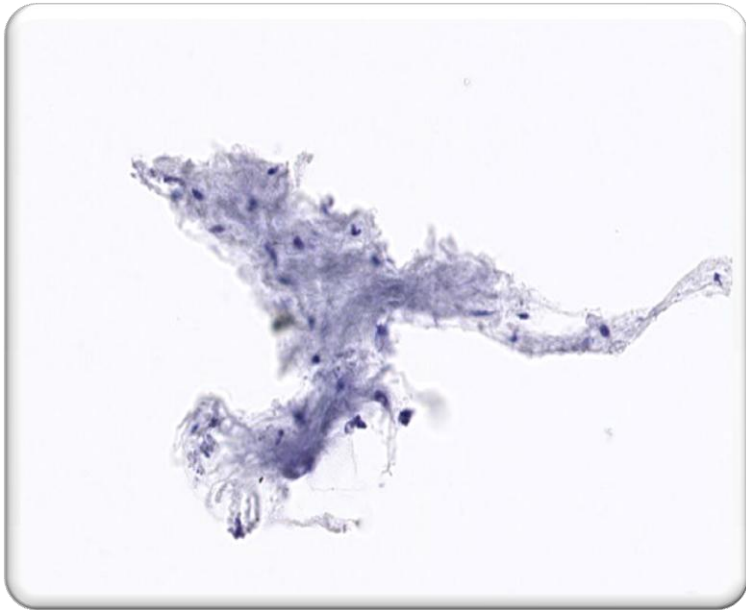Pap, liquid-based cytology



Pap, liquid-based cytology



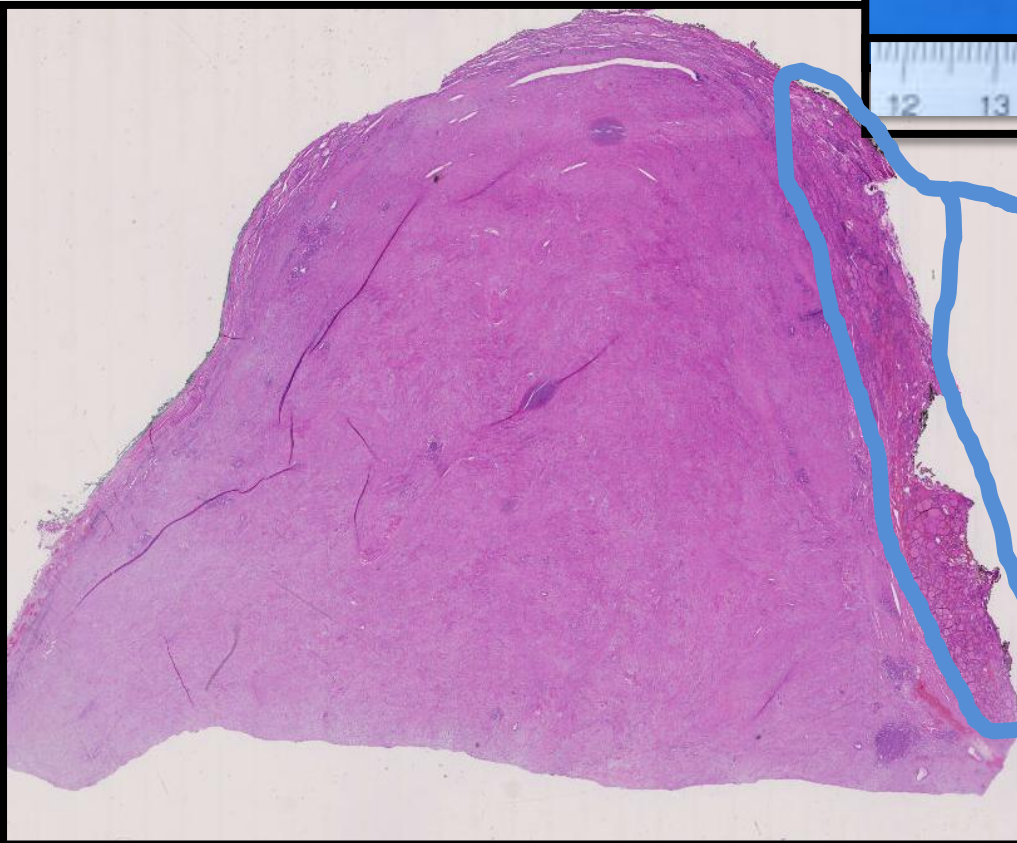
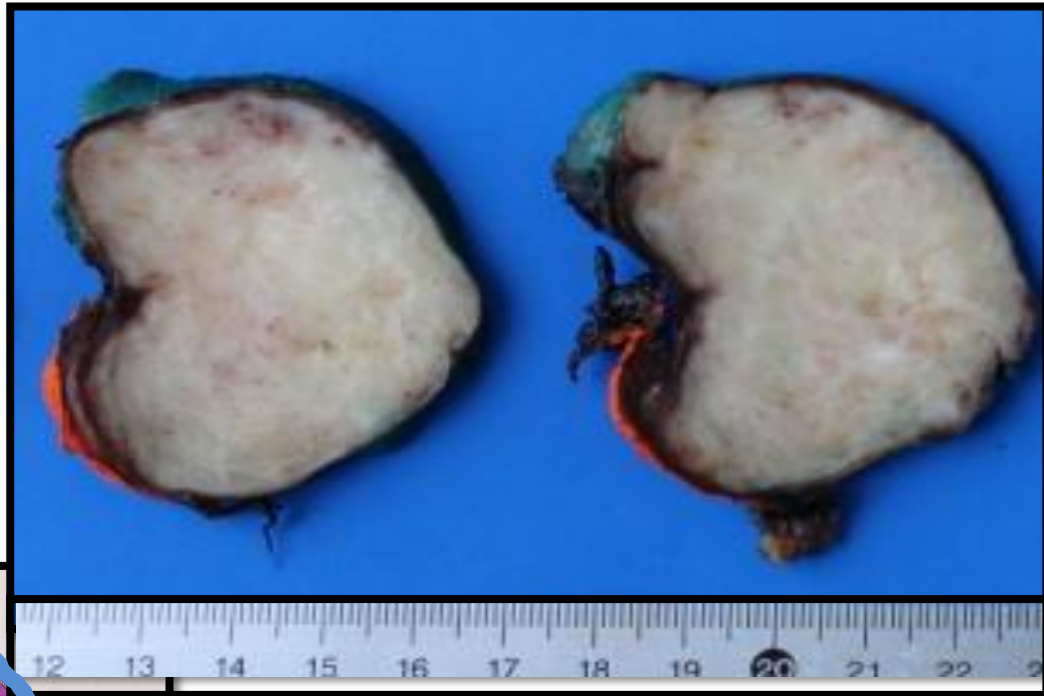
Pap, liquid-based cytology



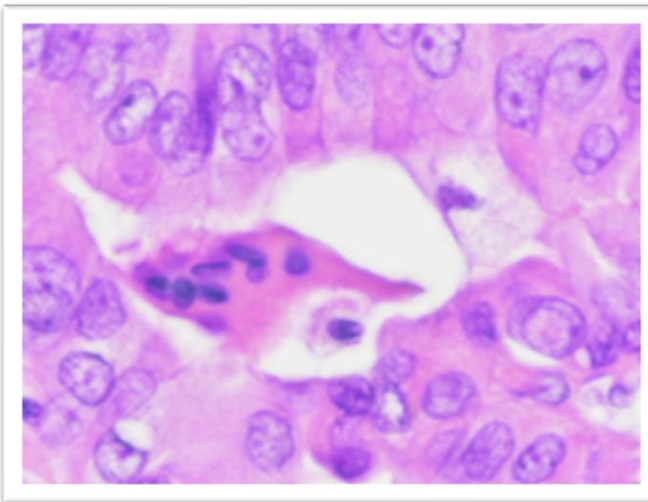
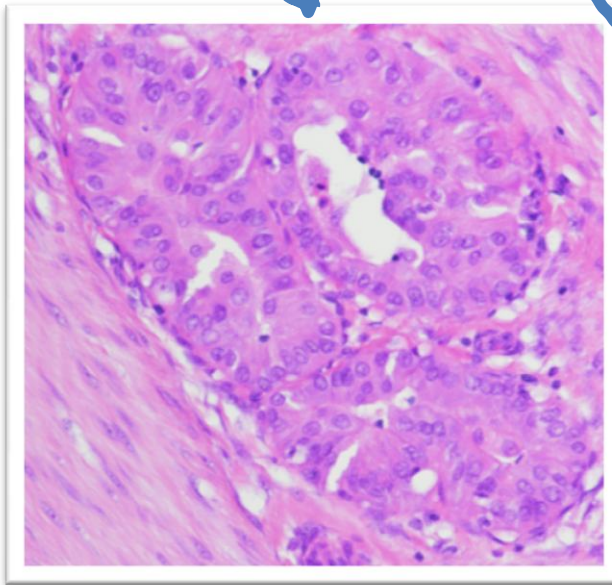
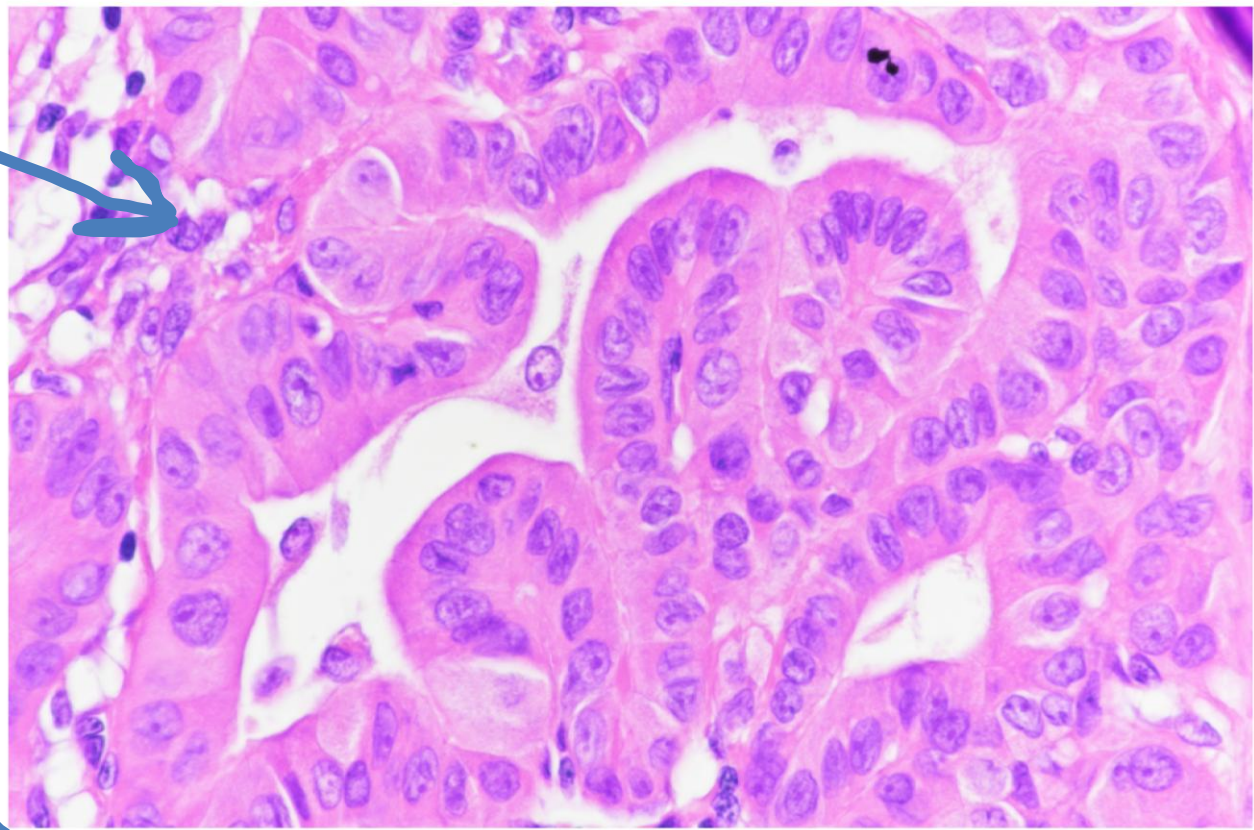
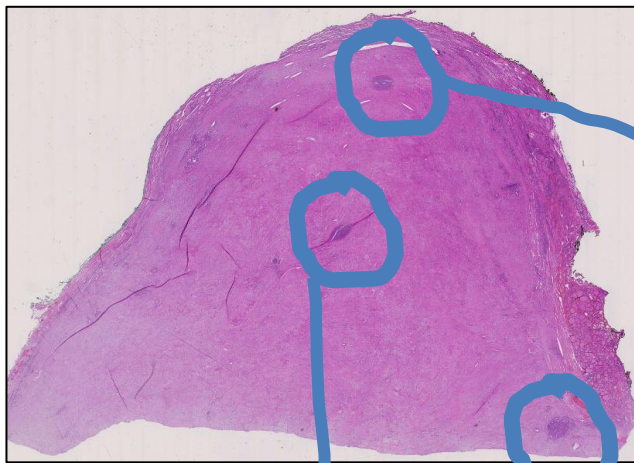
Diagnostic cytologique

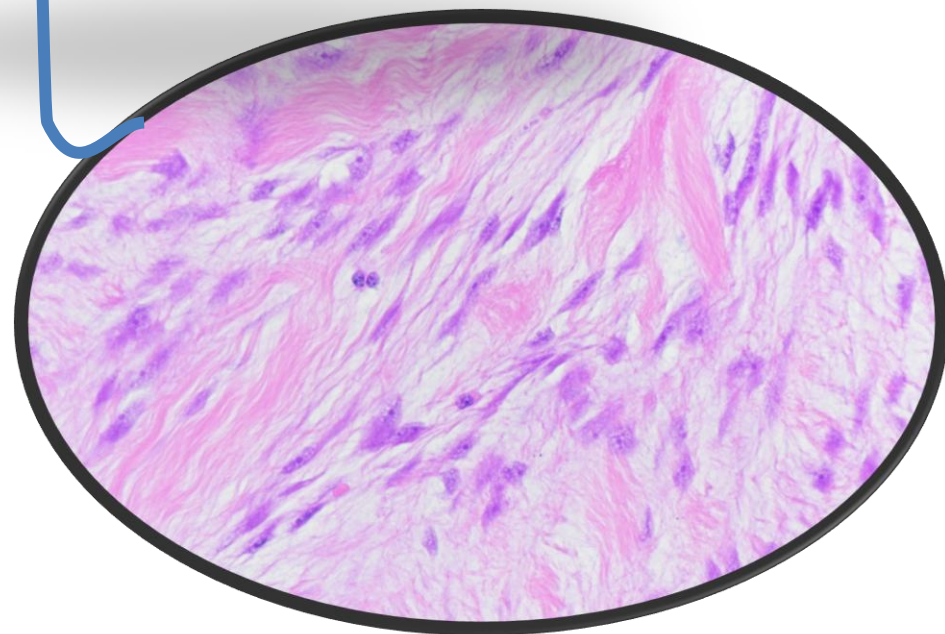
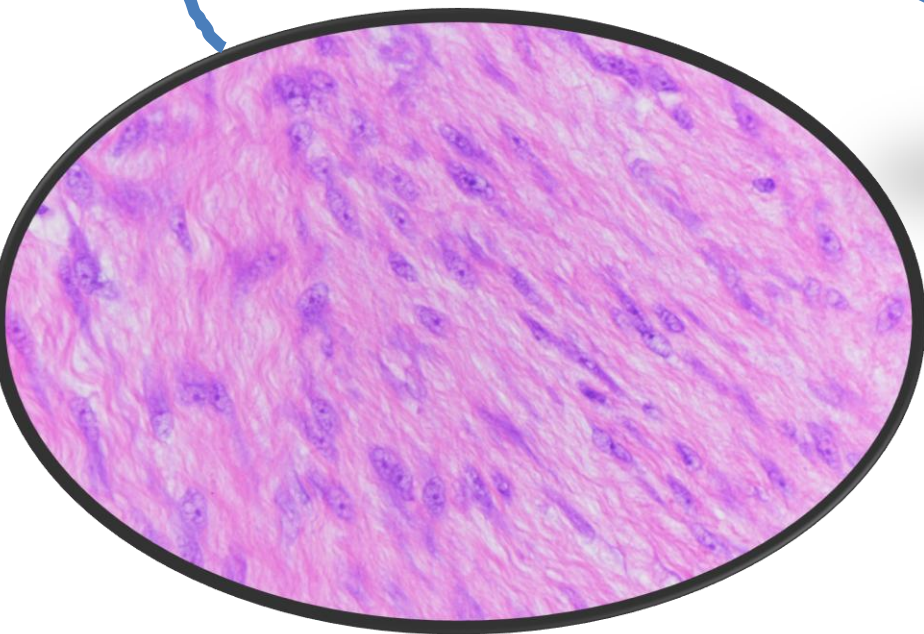
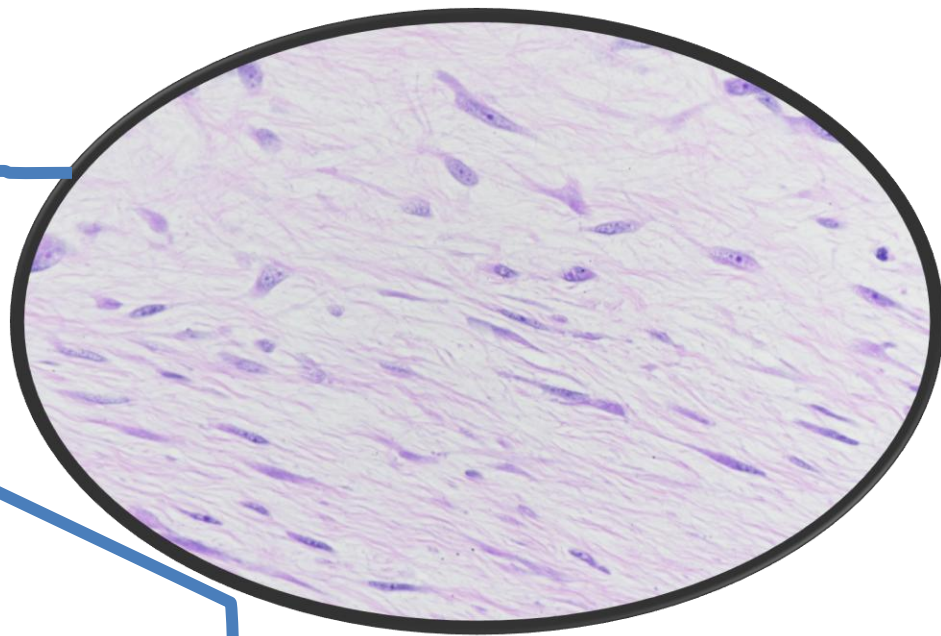
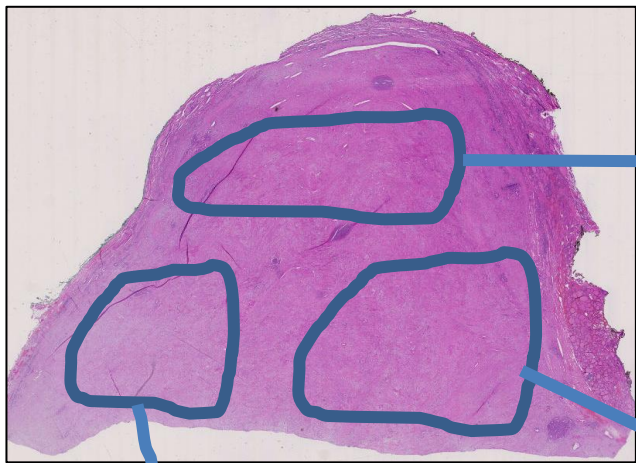
- **AUS/FLUS (atypies cellulaires)
selon la classification de Bethesda
et stroma avec fibrose (??)**

Macroscopie et histologie

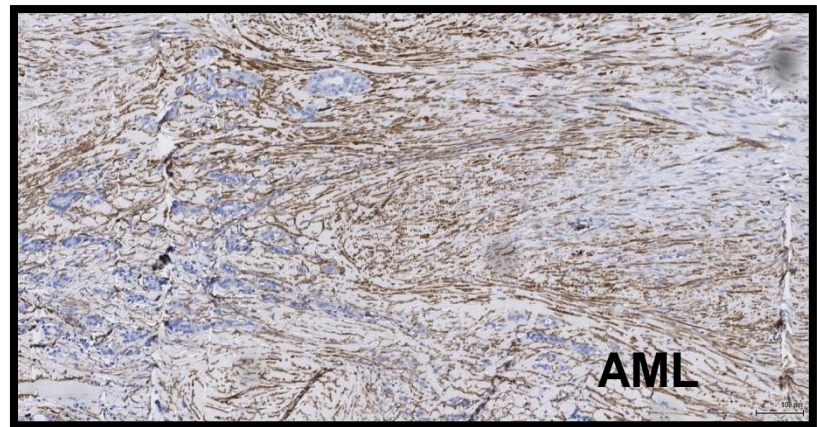
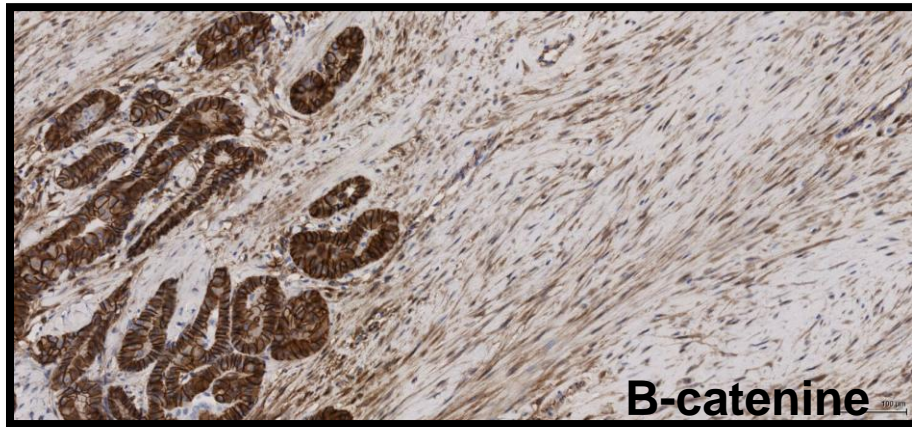
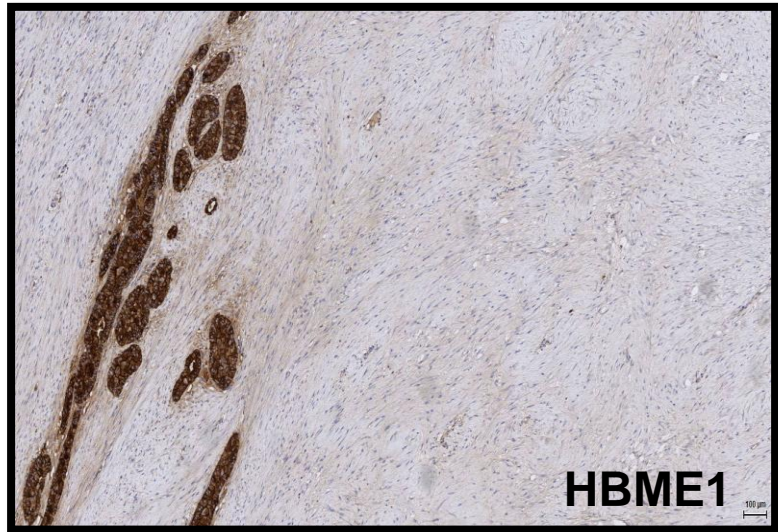
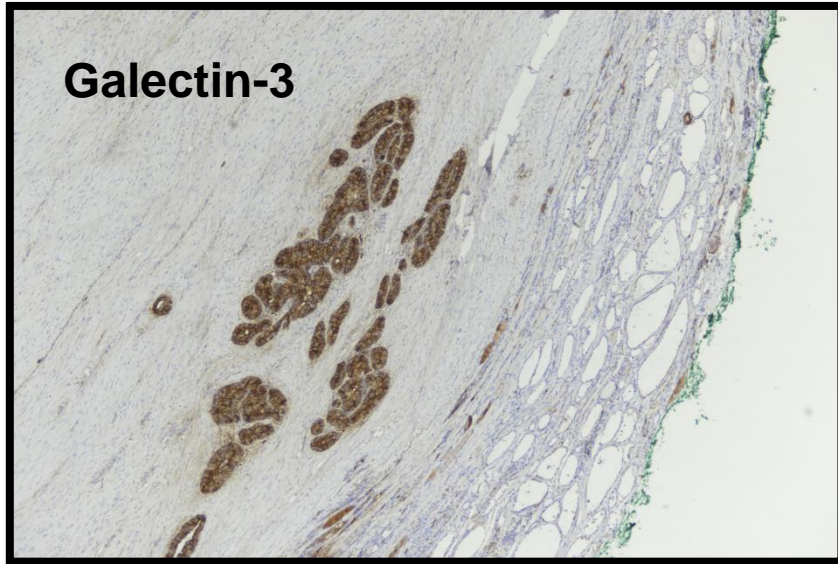


Thyroïde normale





Immunohistochemie



Diagnostic histologique

- **Carcinome papillaire de la thyroïde (5%)
avec stroma de type fasciite nodulaire(95%)**