Femme de 74 ans
Masse de la parotide droite de découverte fortuite

→ **FNA de la parotide droite**

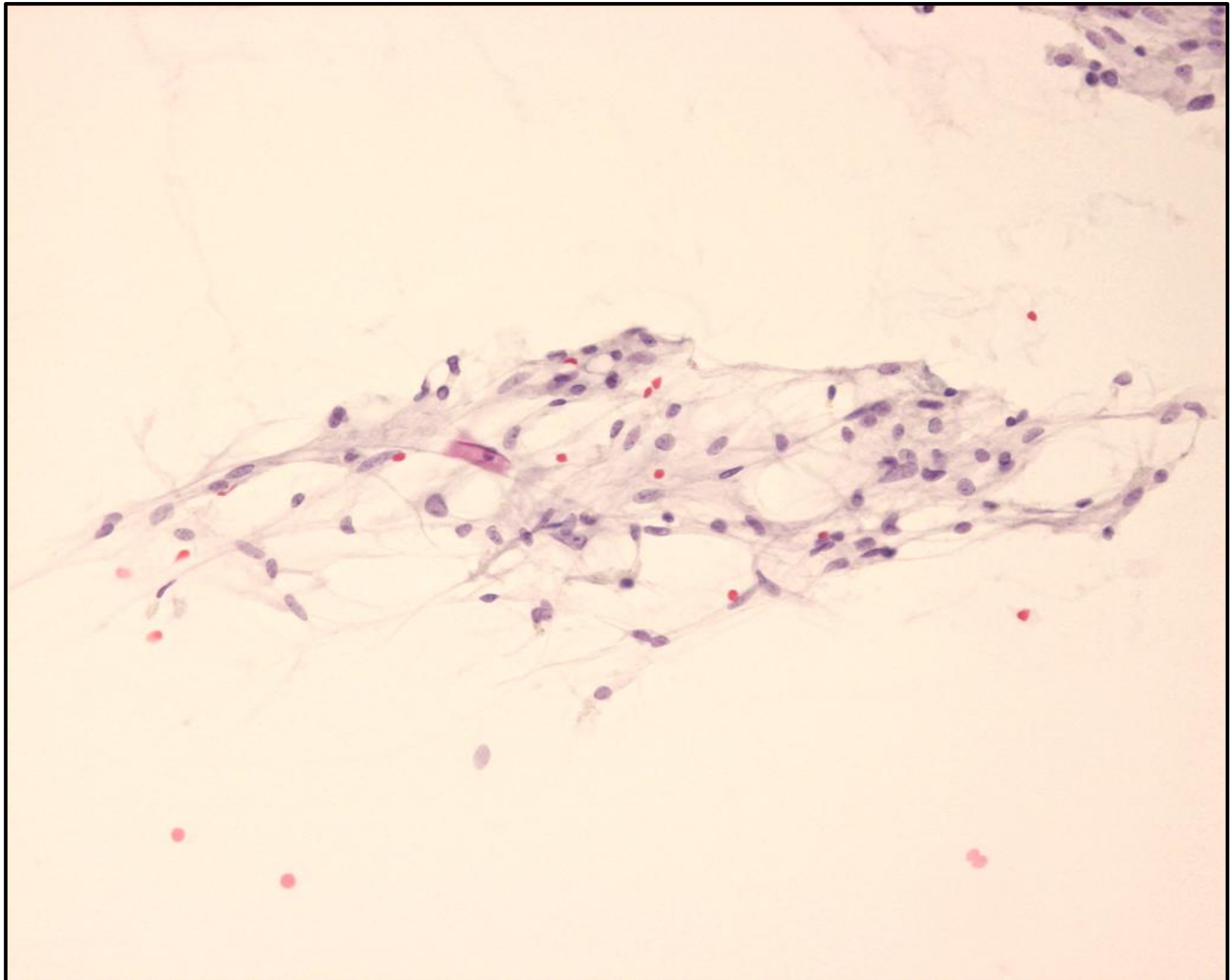

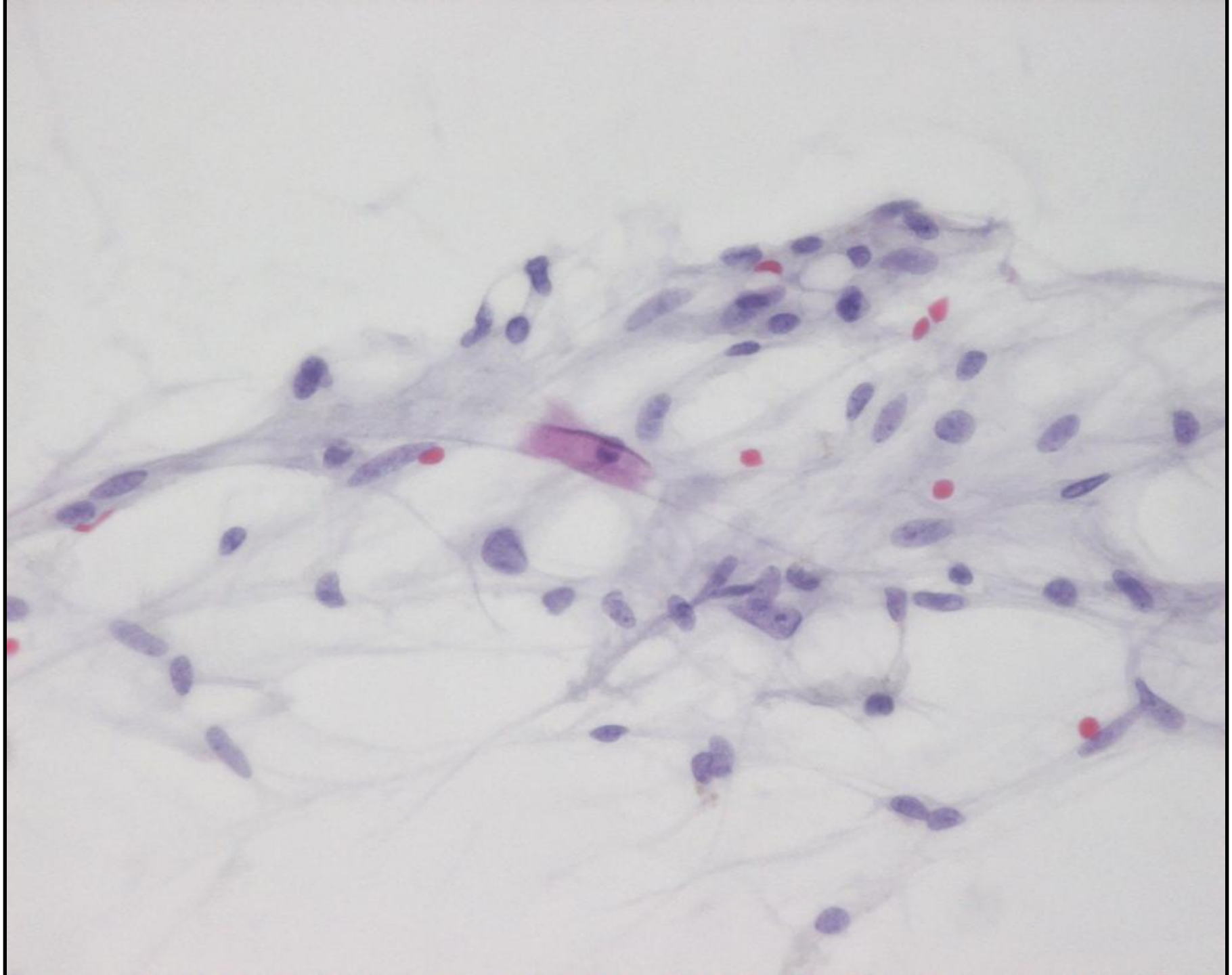

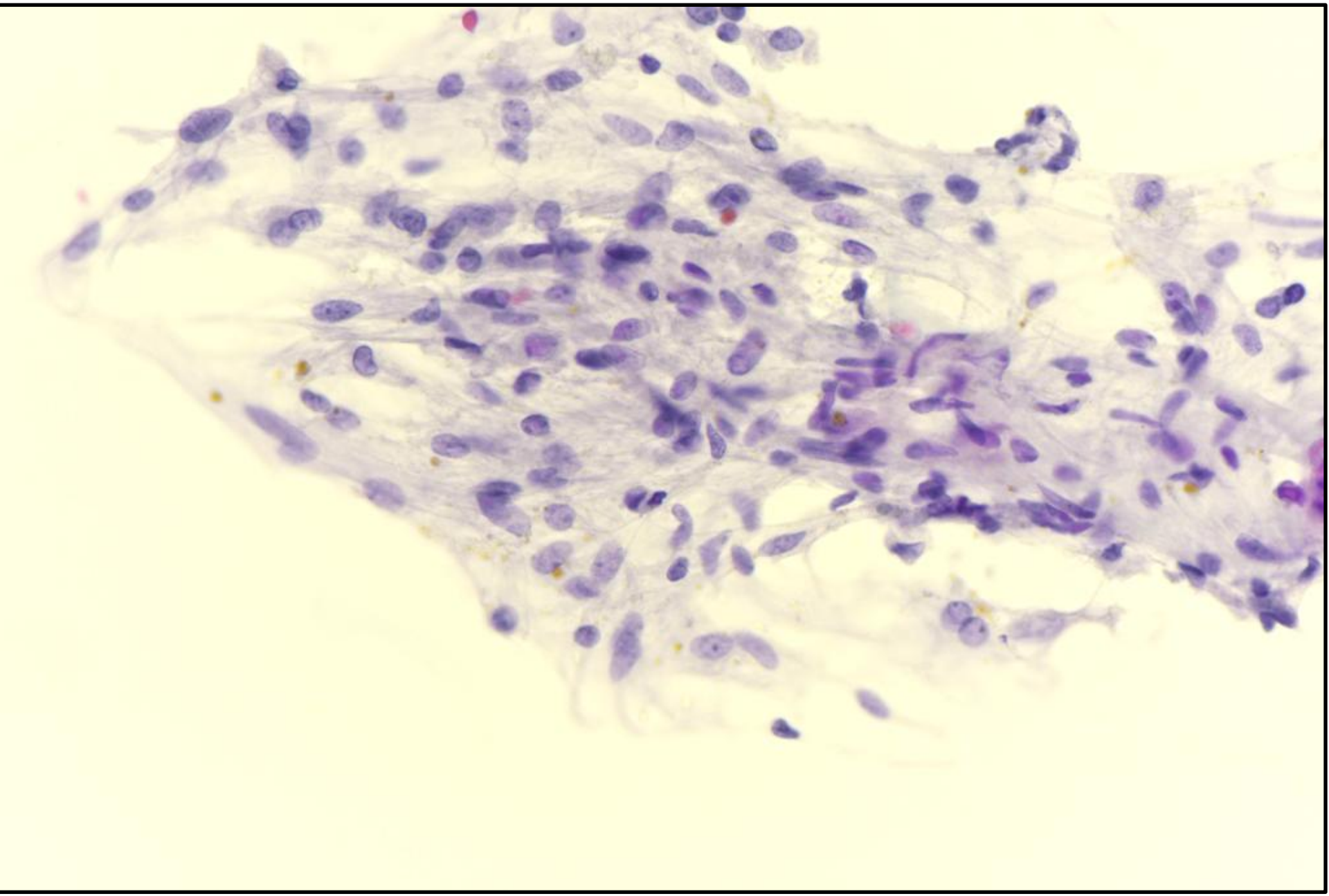

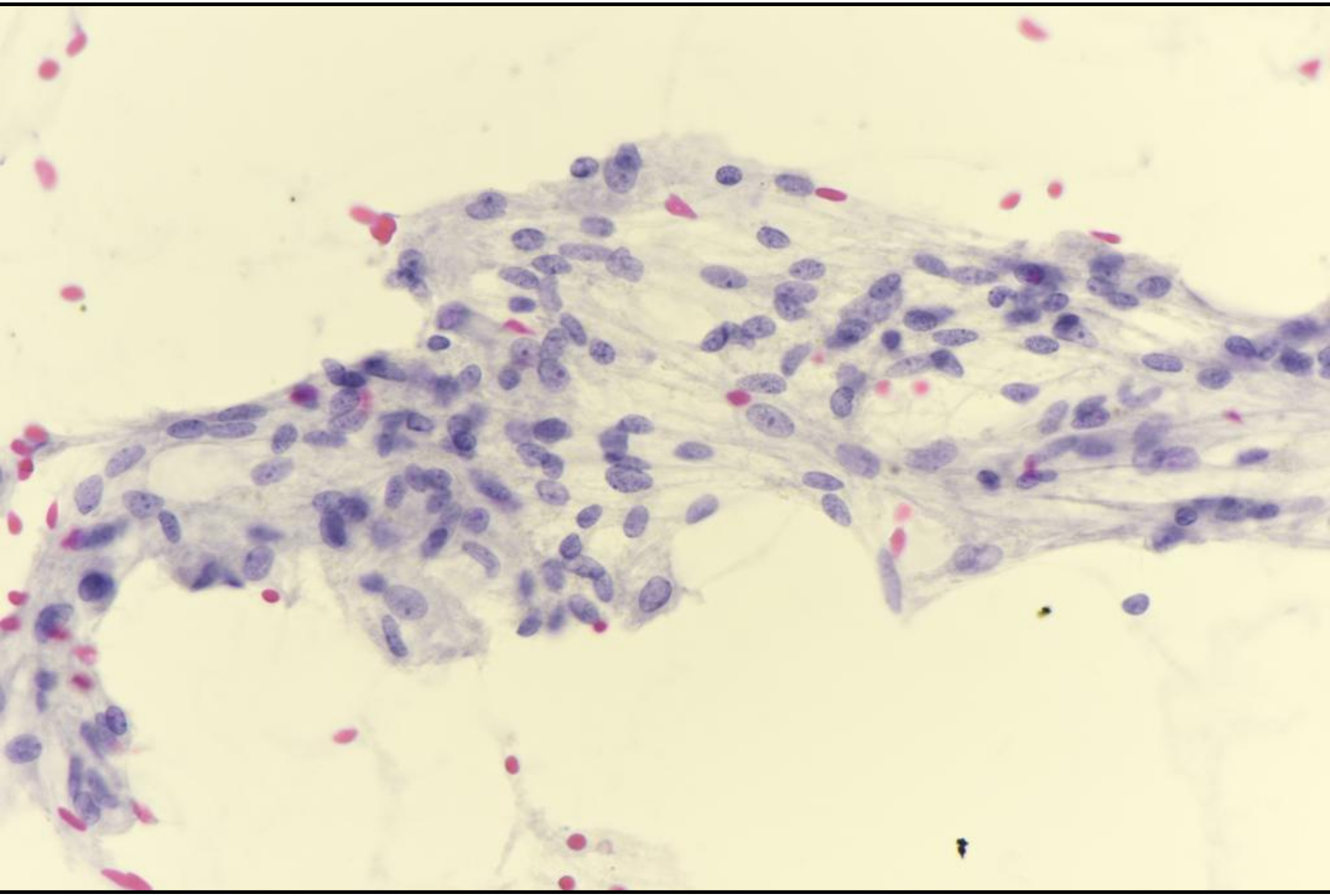

Diagnostic différentiel

- **Myoépithéliome**
- **Schwannome**
- **Lipome**
- **Lipome à cellules fusiformes**
- **Tumeur fibreuse solitaire**
- **Léiomyome**
- **Histiocytofibrome bénin**

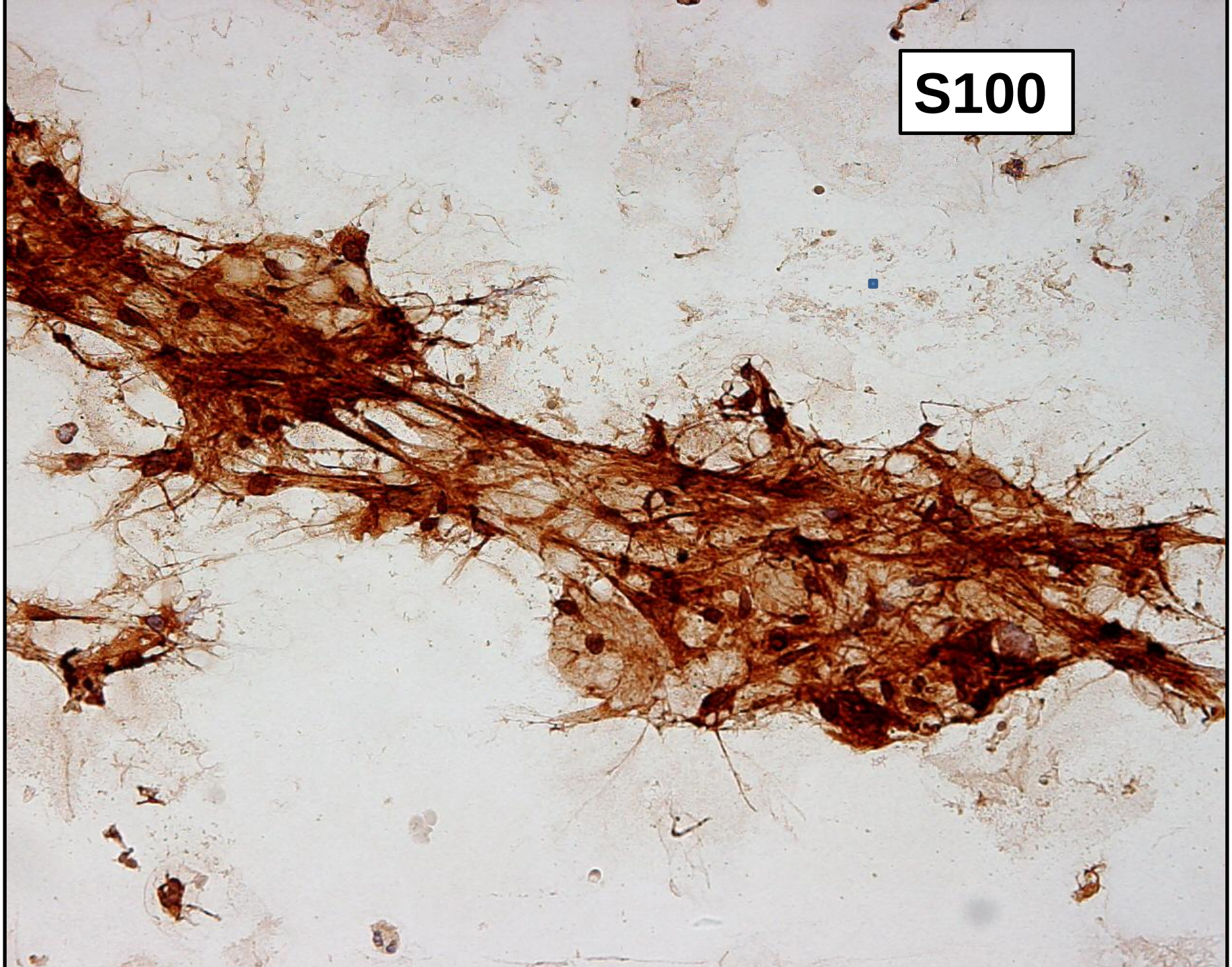
S100

Diagnostic cytologique:

lésion bénigne à cellules fusiformes évoquant en premier lieu un myoépithéliome ou un schwannome

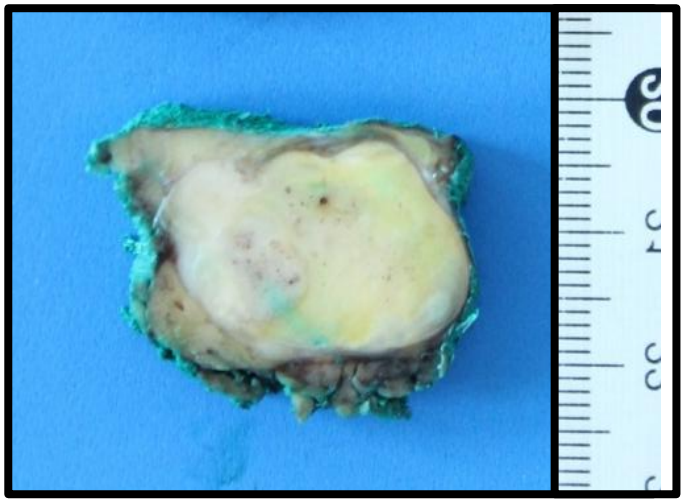

Macroscopie:

Masse de 4 x 3.5 x 3 cm

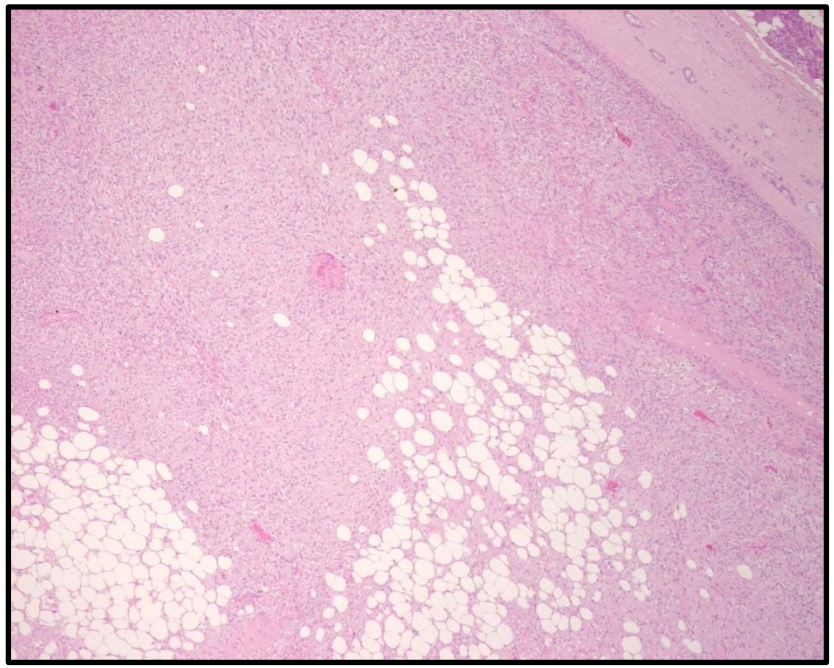

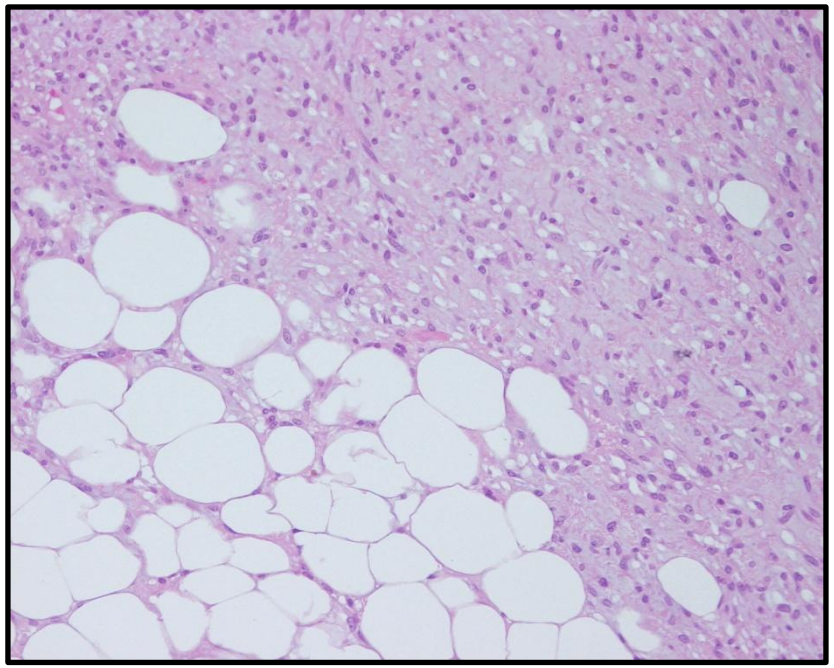

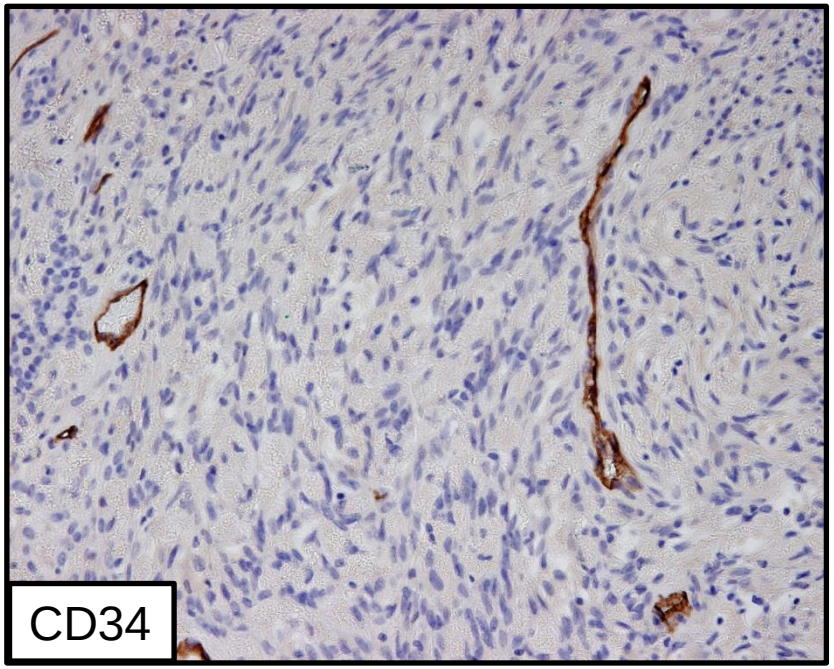
CD34

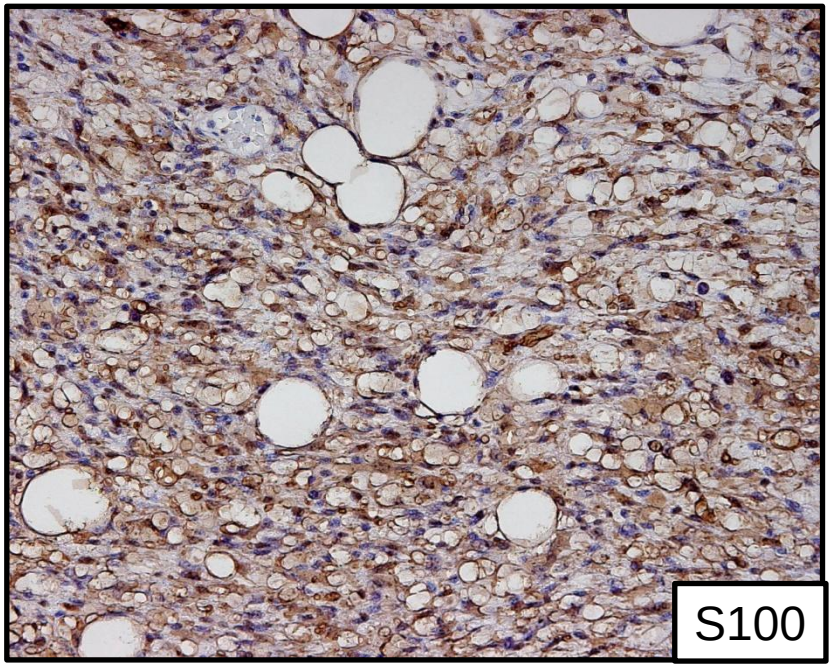
S100

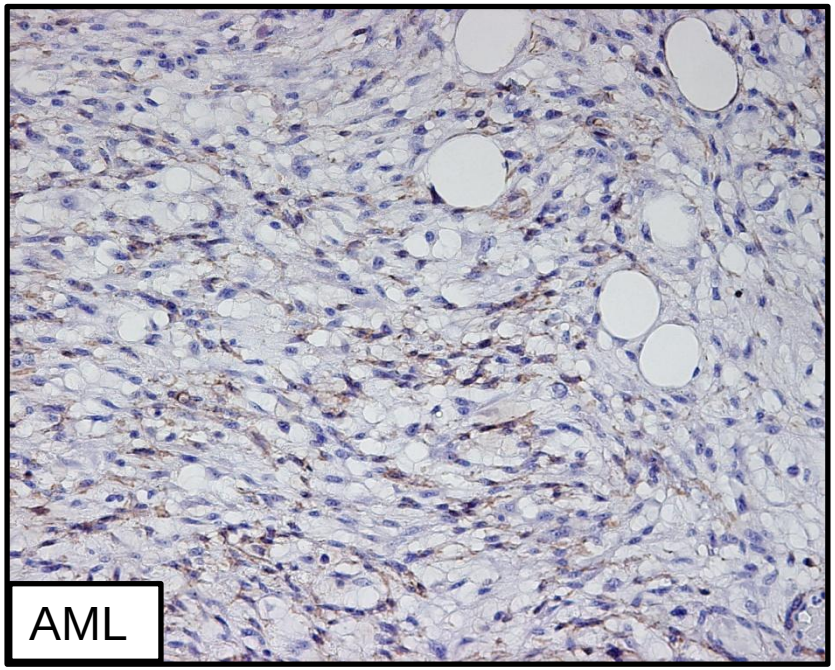
AML

Diagnostic histologique: myoépithéliome avec métaplasie adipeuse extensive

Le myoépithéliome est une lésion rare à évoquer devant une lésion à cellules fusiformes sans stroma myxo/chrondroïde (adénome pléomorphe).

La métaplasie adipeuse peut être extensive et être prise pour une autre lésion (lipome; lipome à cellules fusiformes (S100-)) dont le traitement n’est pas le même.

Diagnostic histologique: myoépithéliome avec métaplasie adipeuse extensive

L'immunocyto/histochimie permet d'exclure les autres diagnostics différentiels:

tumeur fibreuse solitaire: CD34+
léiomyome: AML+

Reference

Virchows Arch (2001) 439:762–767
DOI 10.1007/s004280100469

ORIGINAL ARTICLE

Alena Skálová · Ivo Stárek · Roderick HW Simpson
Vladislava Kučerová · Jana Dvořáčková
Romuald Čuřík · Milada Dušková

Spindle cell myoepithelial tumours of the parotid gland with extensive lipomatous metaplasia

A report of four cases with immunohistochemical and ultrastructural findings

Received: 27 November 2000 / Accepted: 19 March 2001 / Published online: 30 June 2001
© Springer-Verlag 2001

Abstract We report four cases of parotid gland tumours composed predominantly of spindle-shaped myoepithelial cells and mature adipocytes. The central portion of one tumour showed extensive adipose differentiation, whereas in the peripheral parts there were small foci of ductal epithelium arranged in cords and tubules within an abundant myxoid stroma. The other cases were adipose spindle cell myoepitheliomas without an obvious glandular component. Under high-power examination, a transition between modified spindle-shaped myoepithelial cells and adipocytes was observed, and this was confirmed with immunohistochemistry. Ultrastructurally, the modified myoepithelial cells showed intracytoplasmic

Keywords Lipomatous · Adipose metaplasia · Salivary gland tumour · Myoepithelial · Pleomorphic adenoma

Introduction

Epithelial tumours of the salivary gland display great pathomorphological variation. In some neoplasms, this variation is due to the participation of neoplastic myoepithelial cells, which may take several forms, including epithelioid, spindle shaped, plasmacytoid or clear. The most common salivary neoplasm with significant myo-