Cas du mois

Dr.se Tsai Chun-Yi, Cytopathologie, CHUV

Clinical information

- 43 year-old G2P2 female

- Consultation : routine cervical smear, liquid based.

The colposcopic examination performed during the Pap test was unremarkable

Cytological features: smear

- A few atypical epithelial cells ...

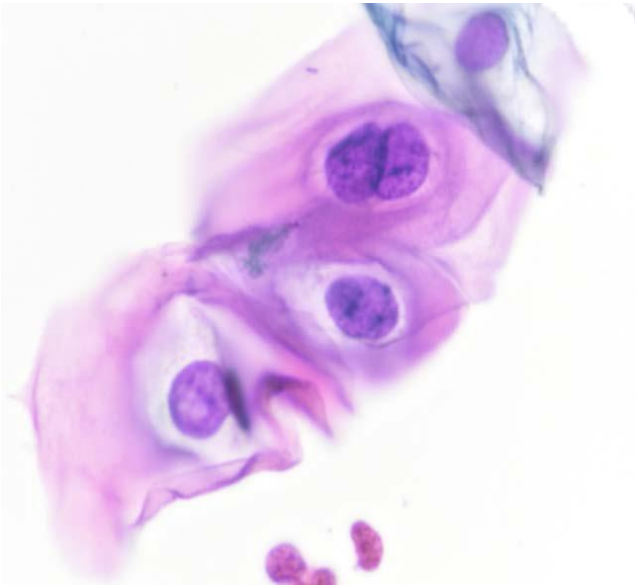

Cytological features: smear

- But also …

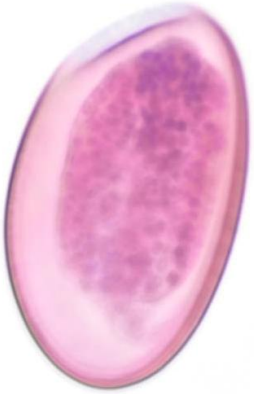

Cytological features: smear

- and ...

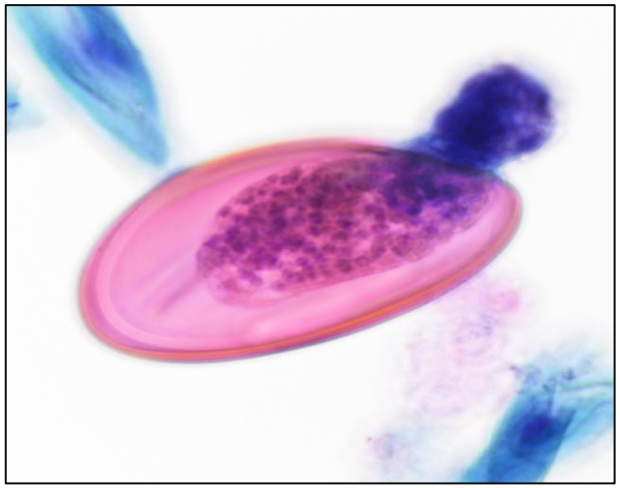

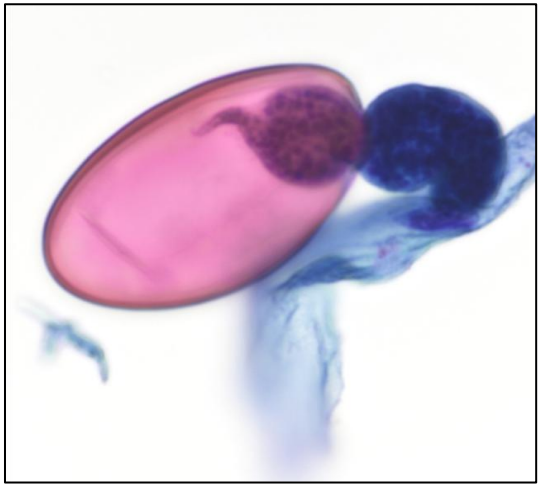

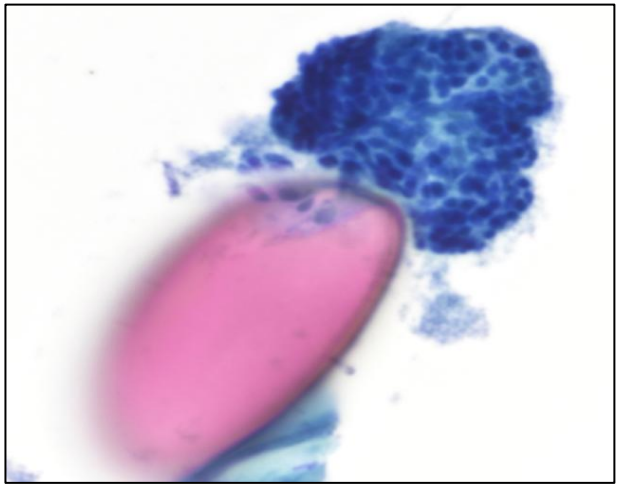

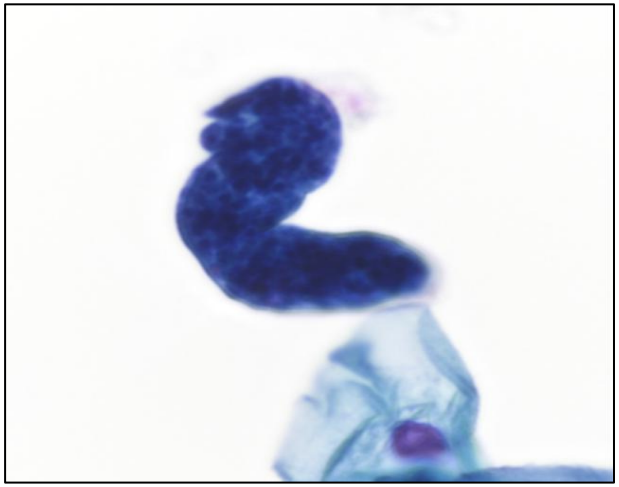

Cytological diagnosis

- A dozen eggs of *Enterobius Vermicularis (EV) !!*
  - some empty
  - some containing granular material
  - some associated with a few embryos

Cytological features: smear

- All possible spectrum of association between eggs and embryos :
  - embryos entirely inside the eggs

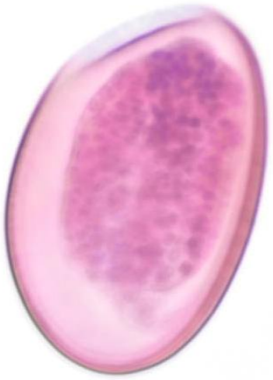

Cytological features: smear

- All possible spectrum of association between eggs and embryos :
  - embryos partially expulsed

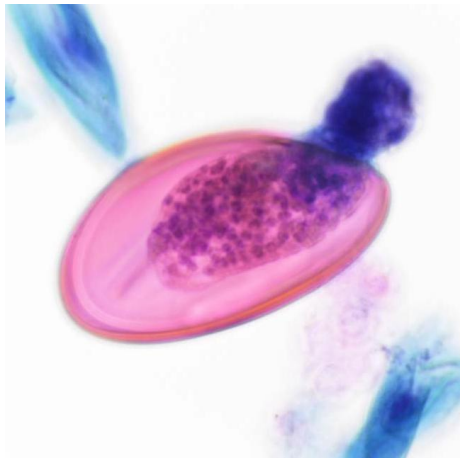
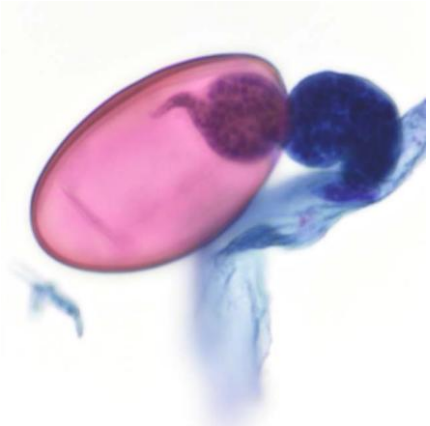
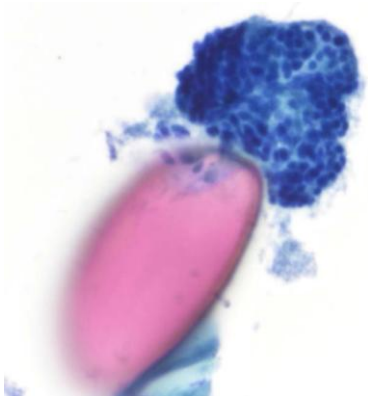

Cytological features: smear

- All possible spectrum of association between eggs and embryos :
  - embryos completely expulsed without any contact with the eggs

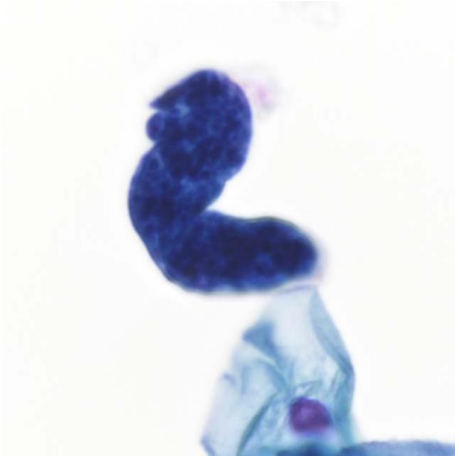

Final cytological diagnosis

“**LSIL and presence of pinworm eggs**”.

Clinical presentation

- The patient was completely asymptomatic.
- According to available medical files*:*

  no intestinal symptoms nor gynecological symptoms reported.

Past medical history

- Patient known for rheumatoid arthritis, currently under immunosuppressive treatment (*Actemra*).
- HPV infection 15 years ago, with cervical low grade squamous intraepithelial lesions (LSIL) and low grade vaginal intraepithelial neoplasia (VaIN1) diagnosed on Pap cytology.
- Laser treatment, with repeated abnormal follow up Pap tests (LSIL and VaIN1) after initial treatment.

Enterobius Vermicularis

Enterobius Vermicularis (EV)

- The most frequent parasitic infection in humans, also called “pinworm”
- Biology: helminth, belonging to the class of nematodes
- Human is the only known host

larger females between 8-13 mm x 0.3-0.5 mm and **smaller males** between 2-5 mm x 0.1-0.2 mm

EV : transmission

Ingestion of the infective eggs, by anus-to-mouth transfer:

- Directly (contaminated hands)
- Indirectly (via contaminated surfaces, textiles)
- Self-infection or person-to-person transmission
- Airborne transmission also possible

EV : life cycle

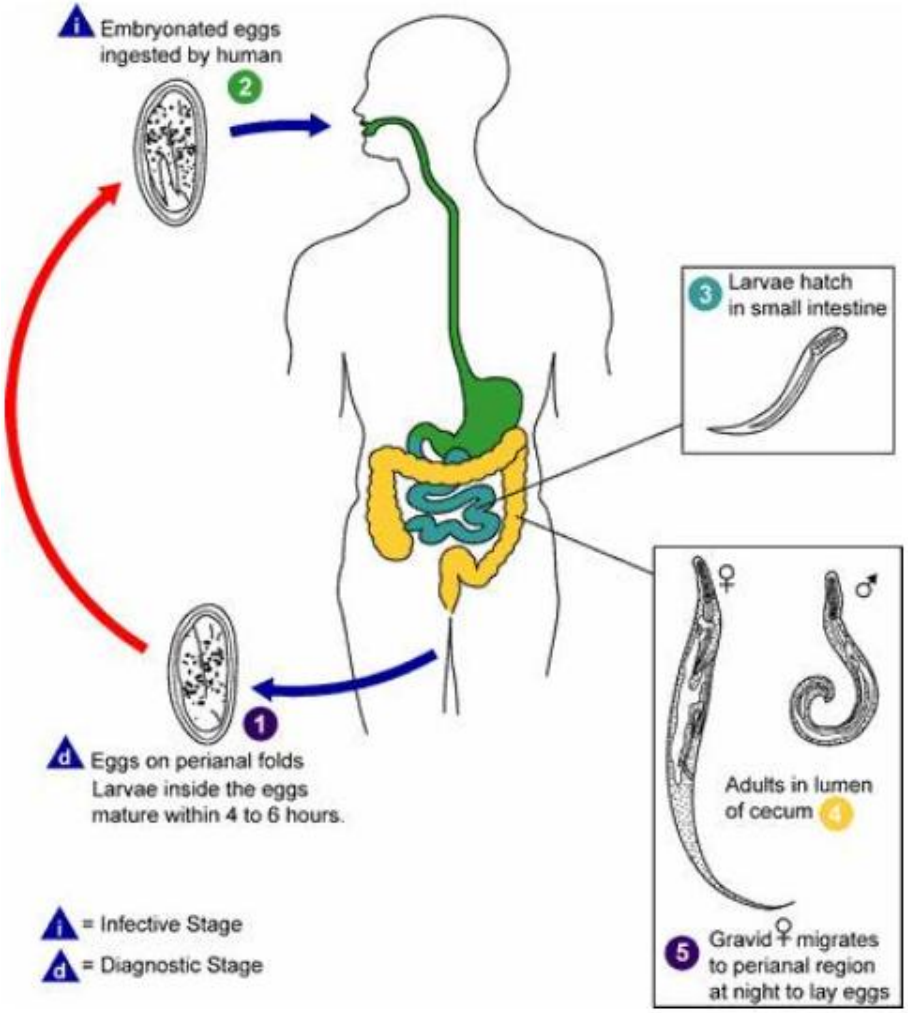

EV: life cycle

1. Once ingested, the larvae contained inside the eggs are released in the small intestine
2. The adult worms spread in the cecum and colon
3. Gravid females migrate at night to the perianal region where they lay their eggs
4. Rarely, EV may penetrate the vagina!

Enterobiasis: clinical presentation

- Variable: many patients asymptomatic.
- Intestinal enterobiasis:
  - perianal pruritus, secondary excoriations +/- bacterial superinfection
  - anorexia and abdominal pain
- Vaginal enterobiasis:
  - Symptomatic in < 30% of cases (vaginitis)!

Vaginal enterobiasis

- Rare! only few cases reported
- Pap Test = important diagnostic tool: identification of EV eggs.

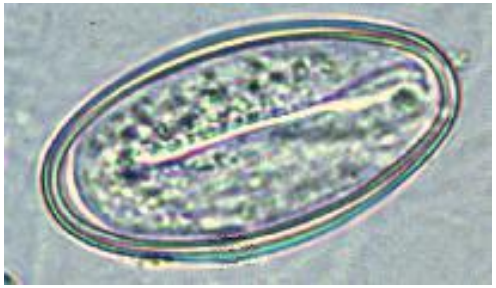

<u>Eggs: specific cytological features :</u>
-ovoid, measuring 50-60 µ in length and 20-30 µ in width
- characteristic thick, double contoured birefringent shell.
- some of them contain coarsely granular embryos or curved larvae

Vaginal enterobiasis

- Must be diagnosed and treated : risk of ascending infection of the genital tract!

- Cytologic differential diagnosis:
  - contamination of the vaginal samples
  - other parasitic ova
  - contaminant vegetable cells