Male, 57 yo.

Left parotid gland, 6 cm mass,
4 years evolution

→ FNA

C. Brunel, M. Bongiovanni, CHUV, Lausanne

Pap, ThinPrep

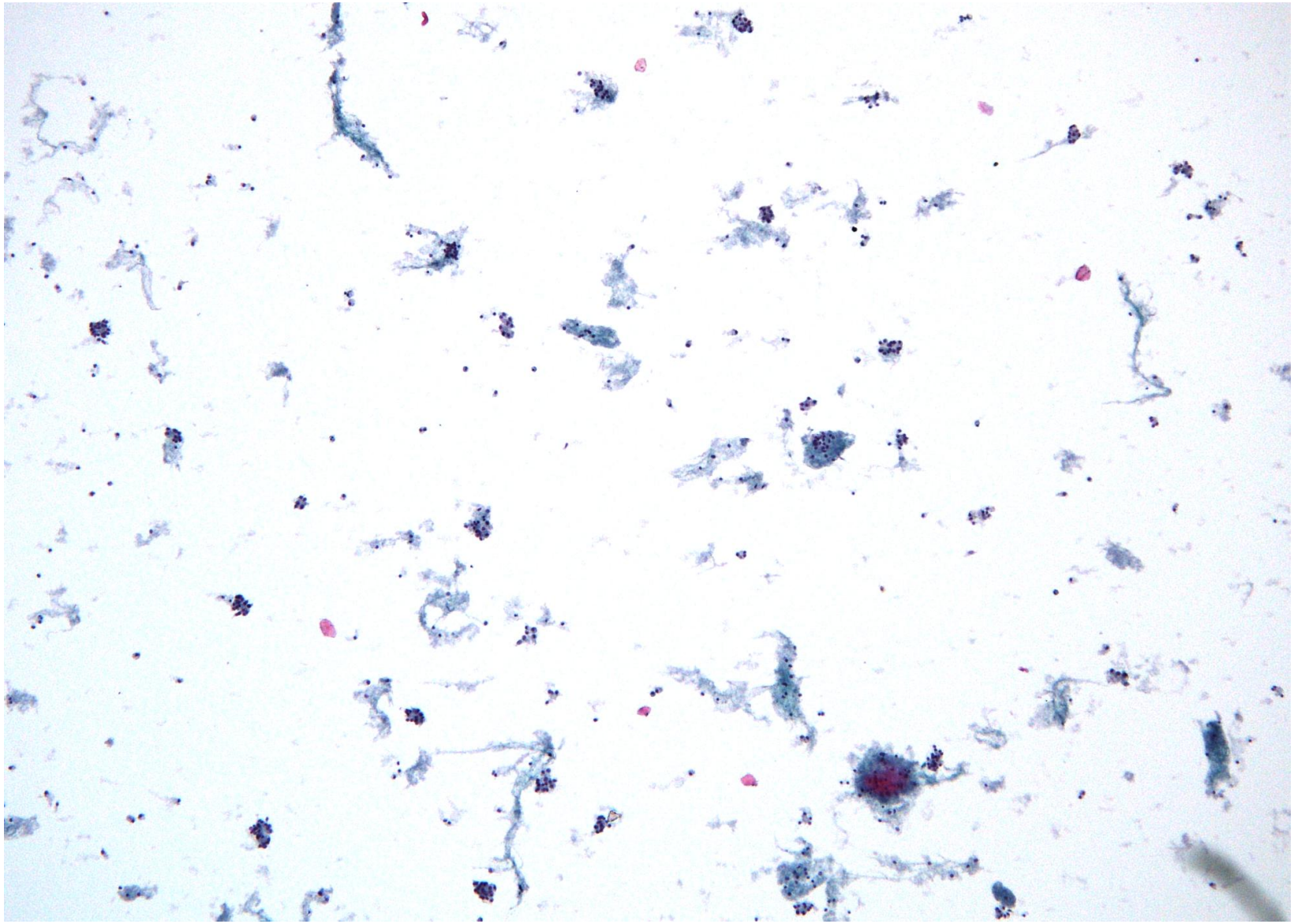

Pap, ThinPrep

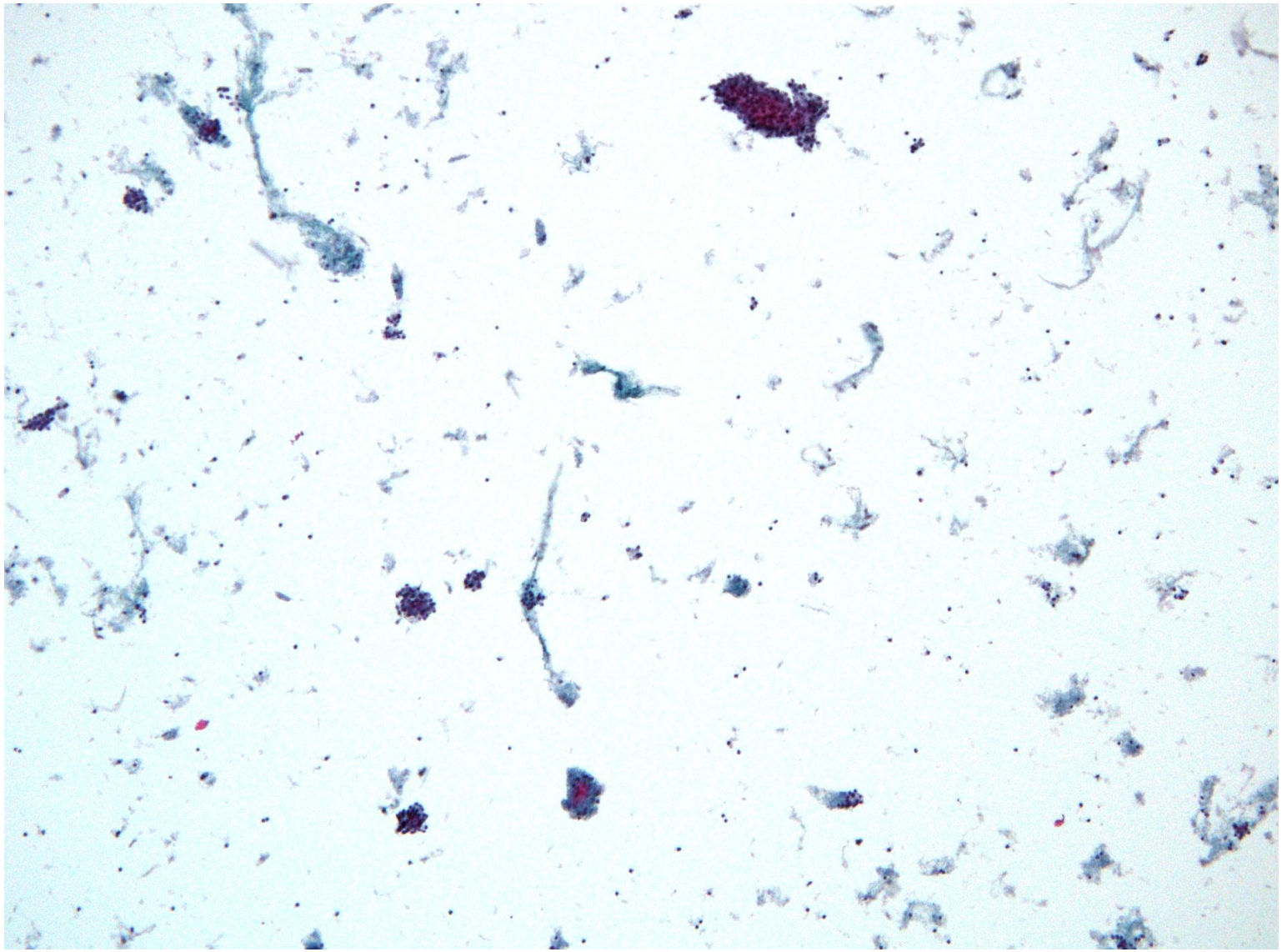

Pap, ThinPrep

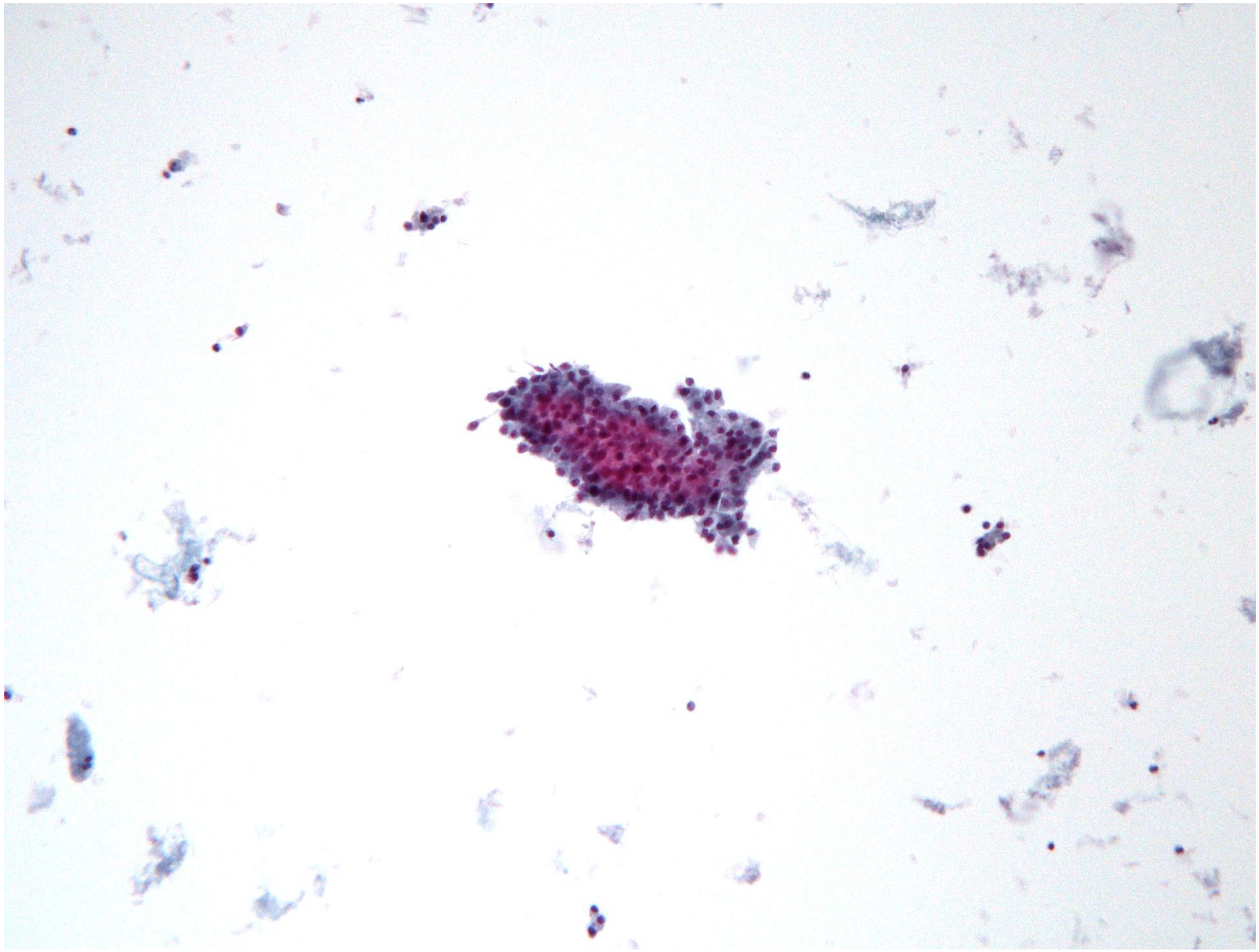

Pap, ThinPrep

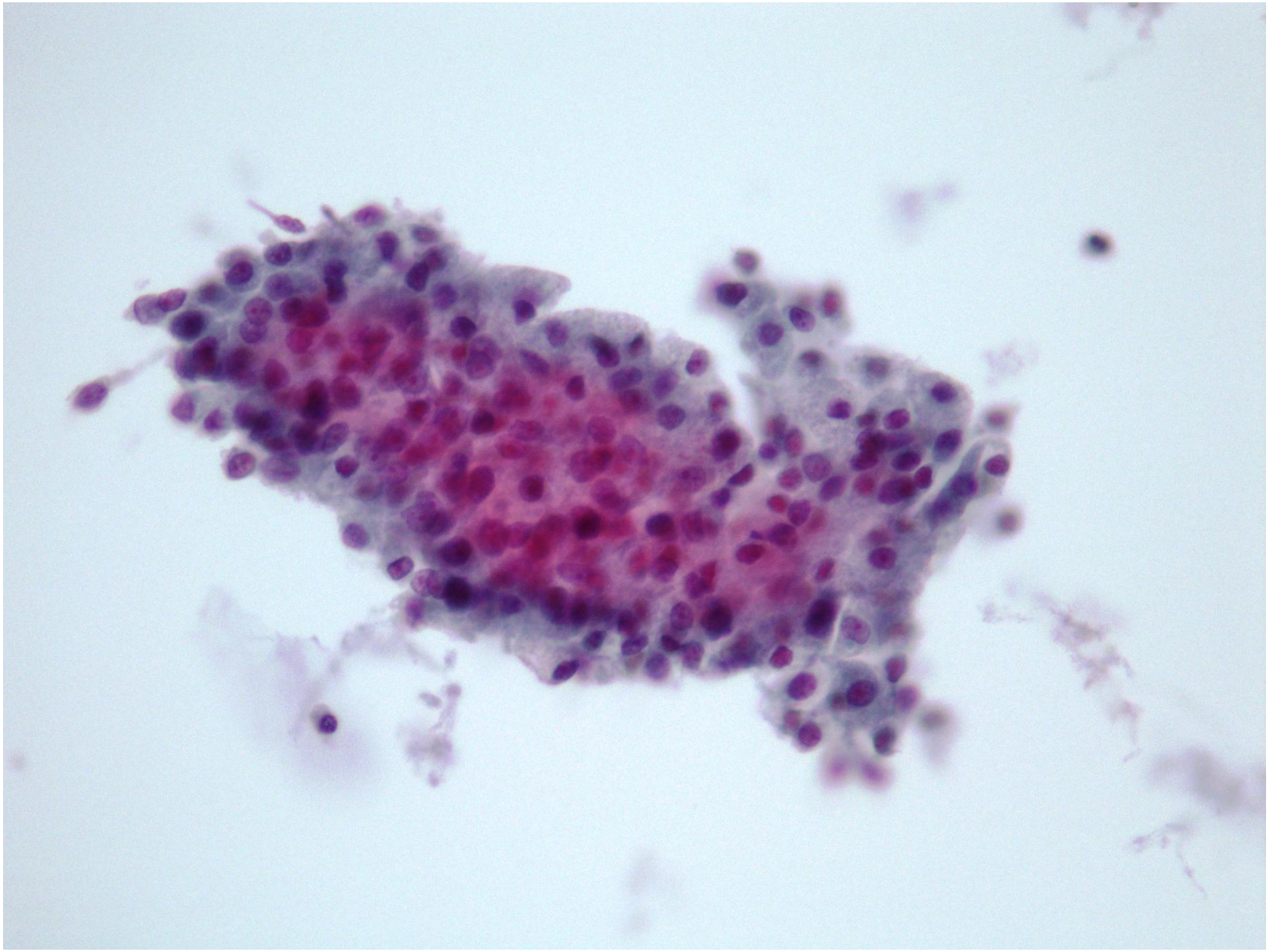

Pap, ThinPrep

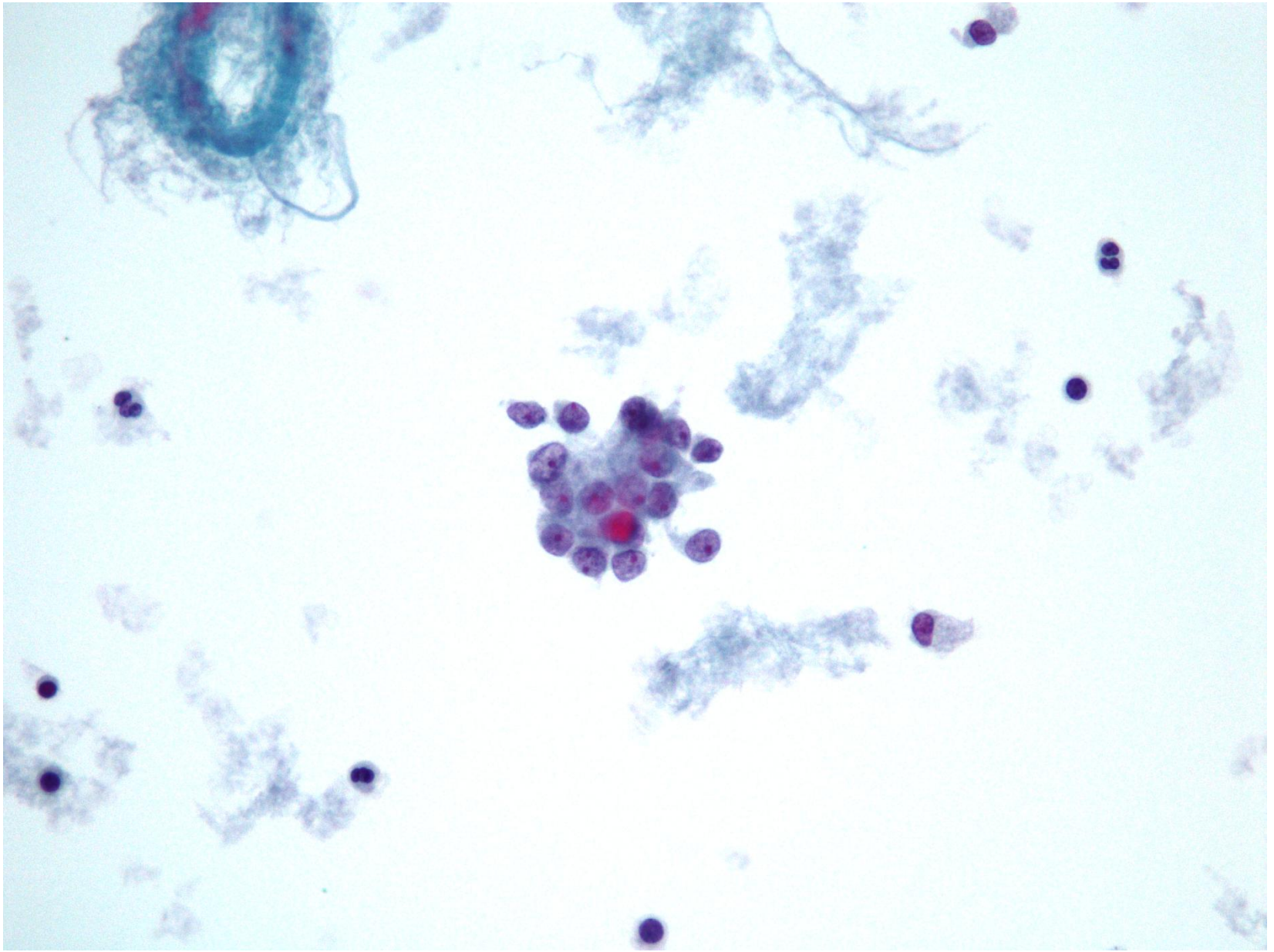

Pap, ThinPrep

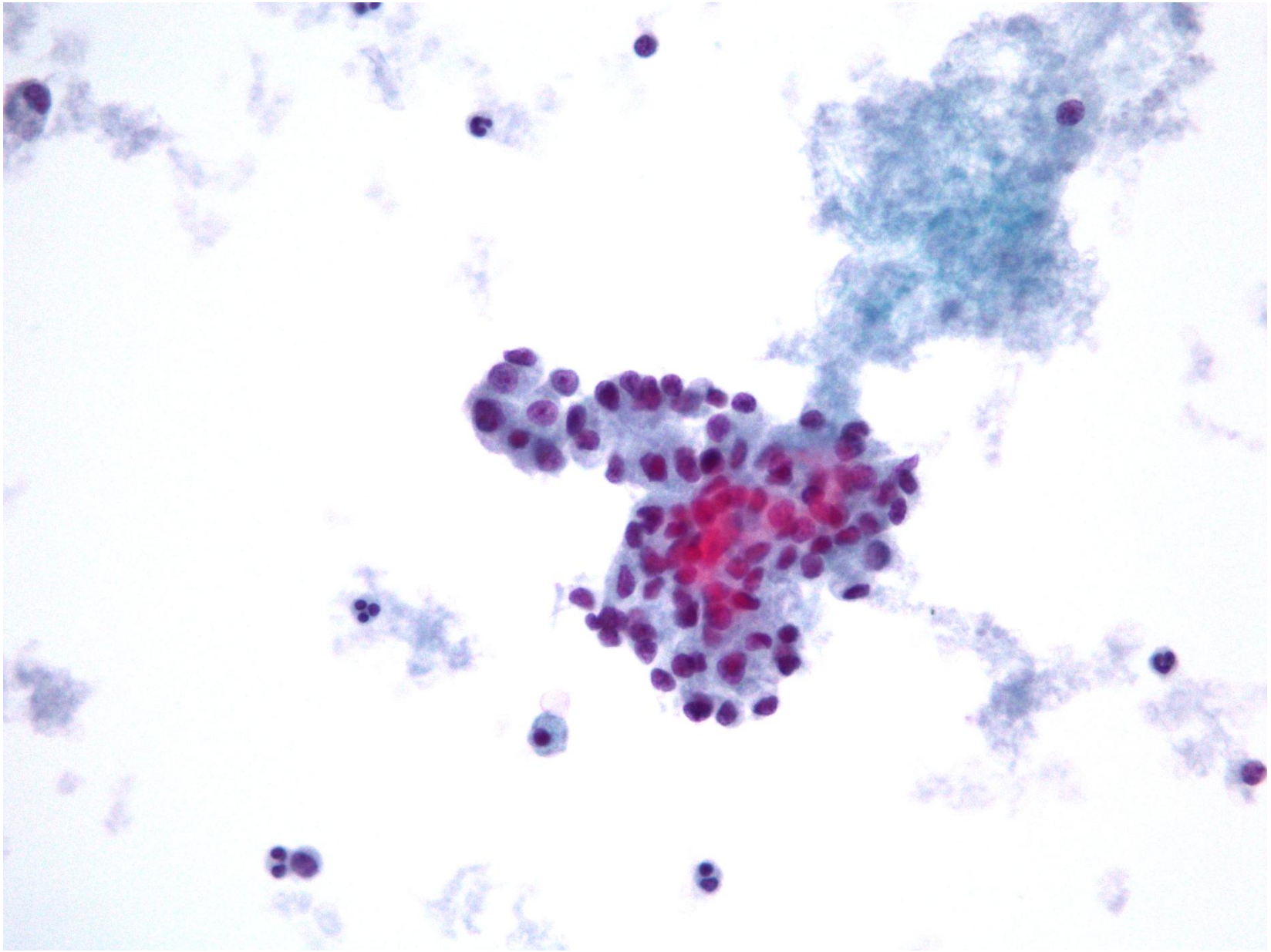

Pap, ThinPrep

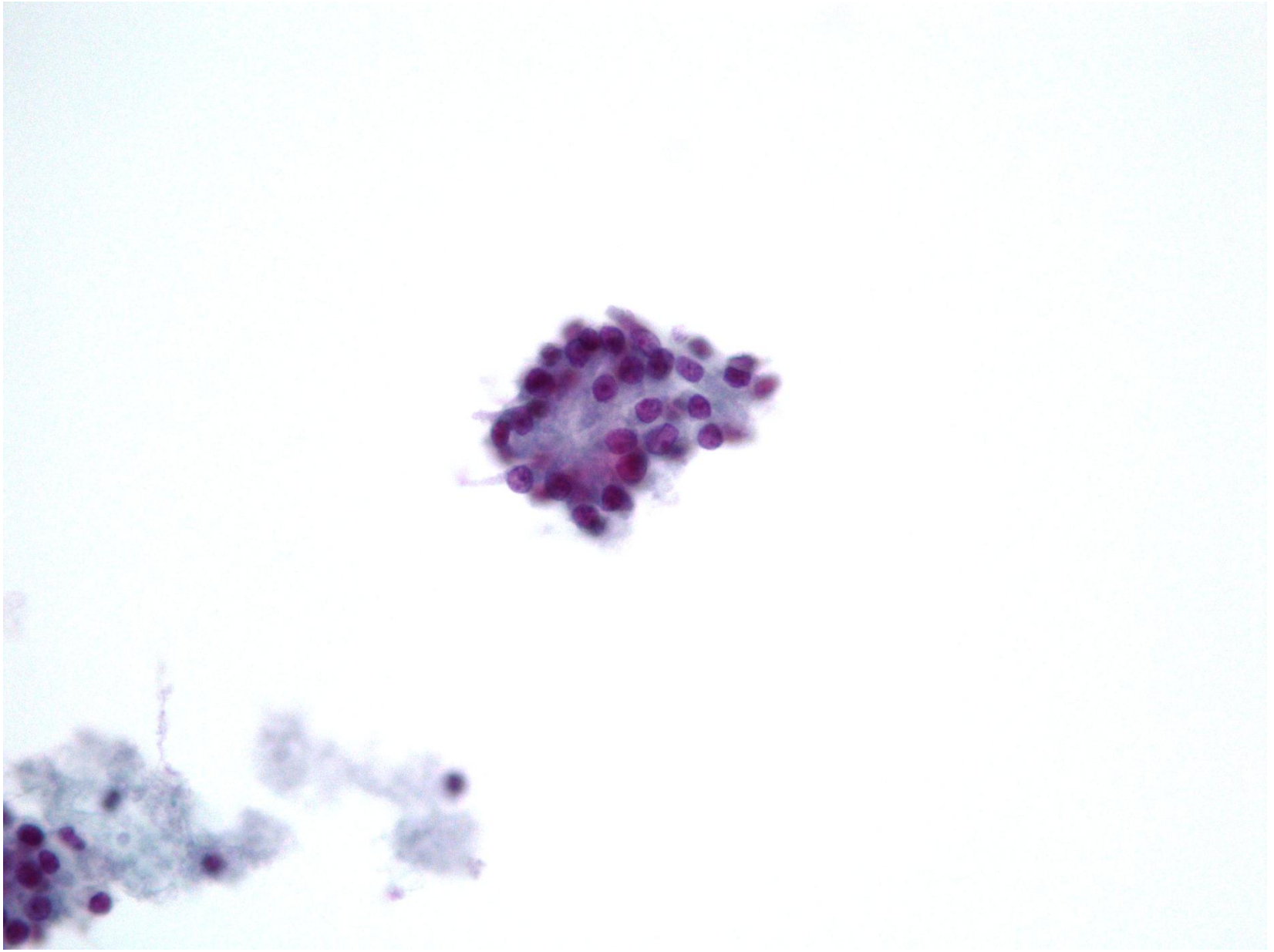

H&E, Cell Block

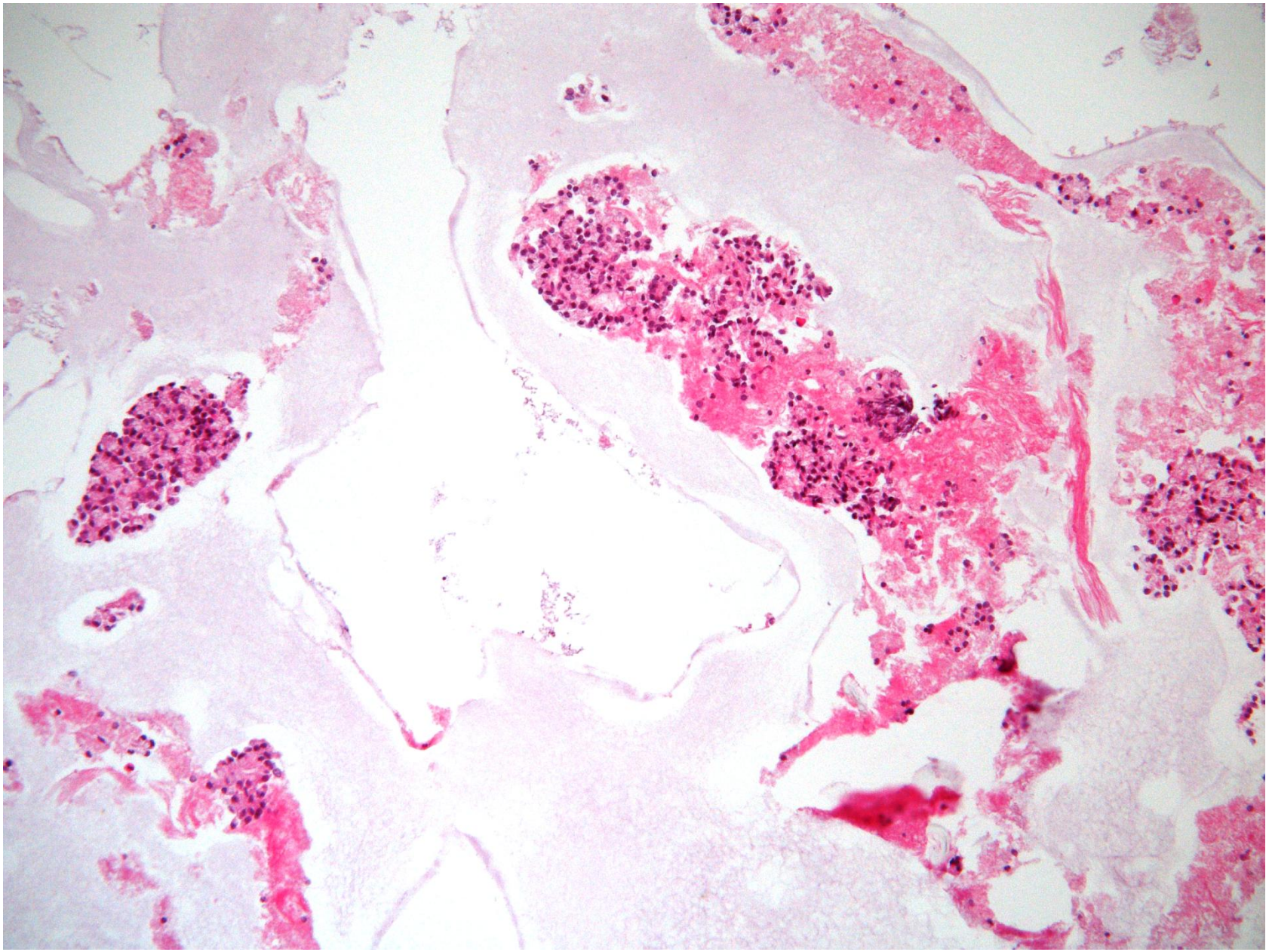

H&E, Cell Block

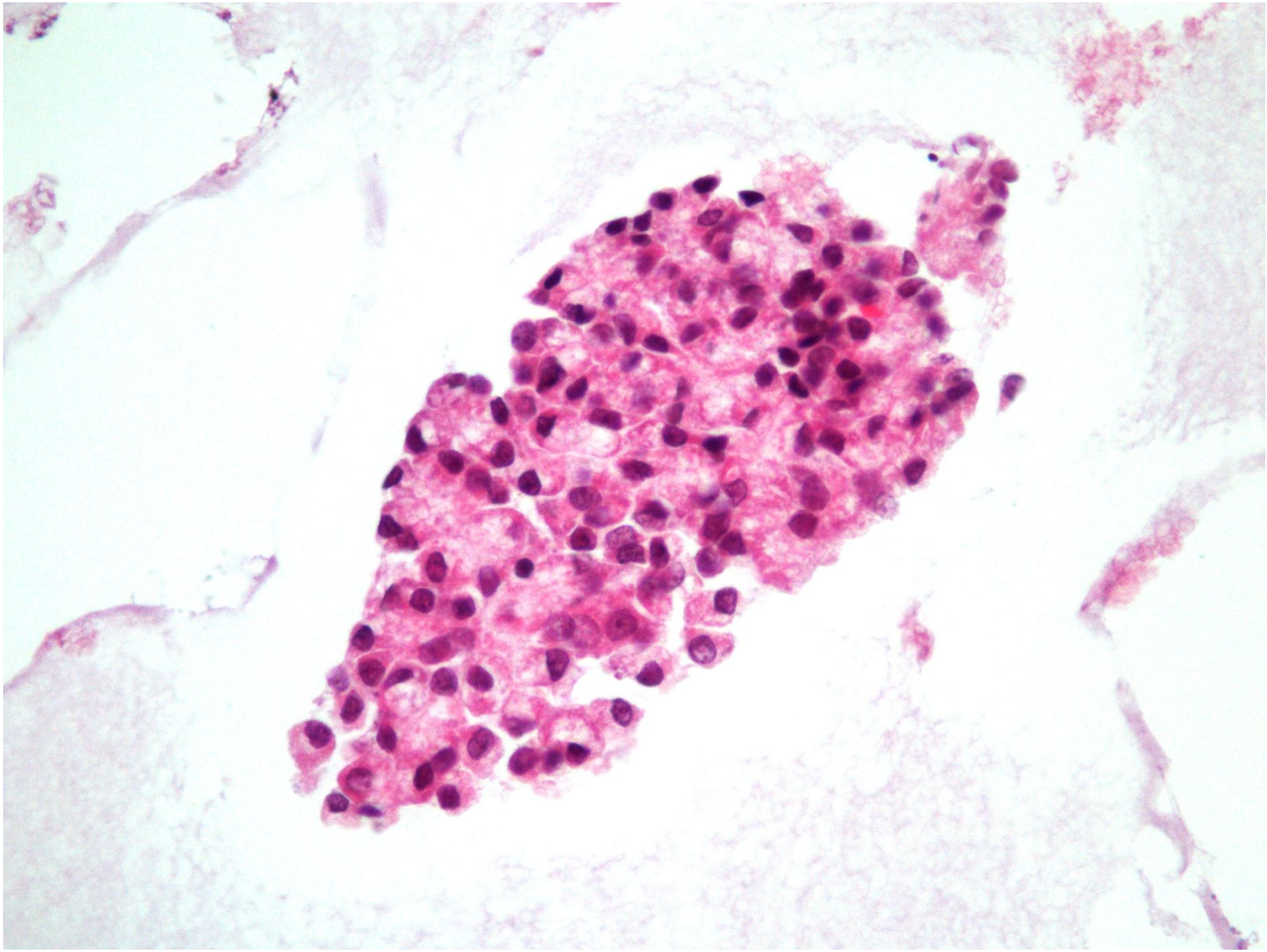

H&E, Cell Block

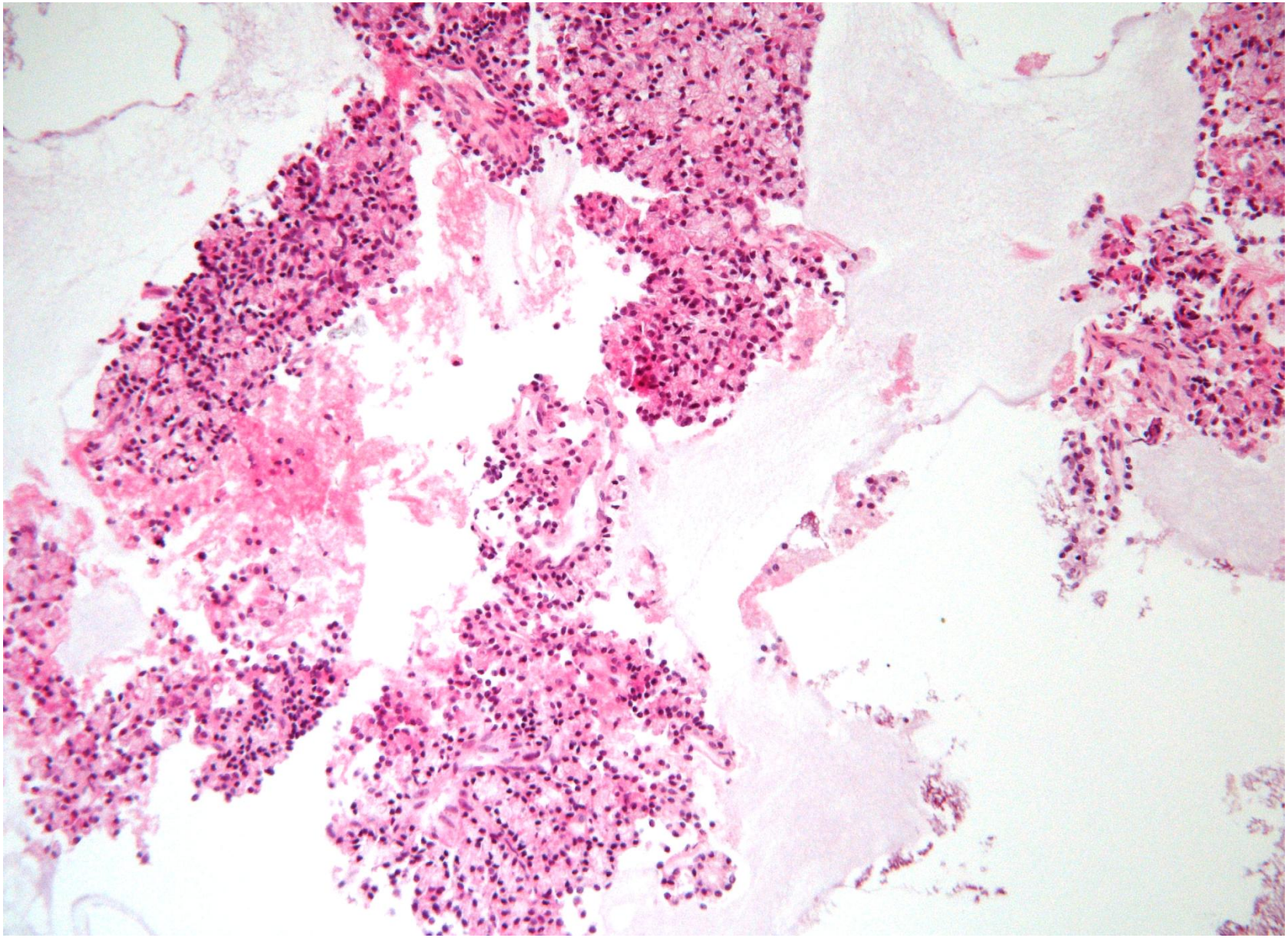

H&E, Cell Block

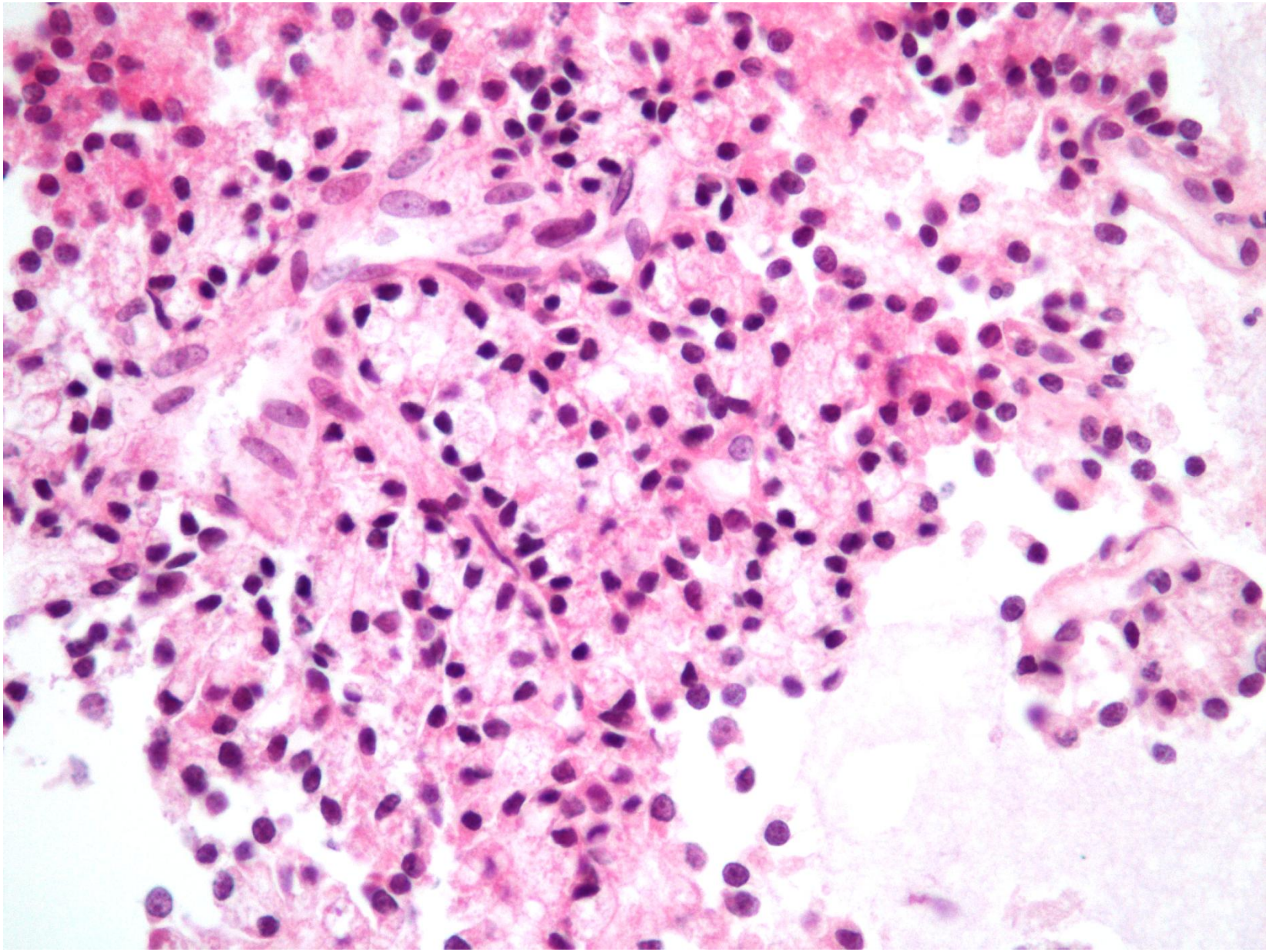

Immunohistochemistry, CKAE1/AE3

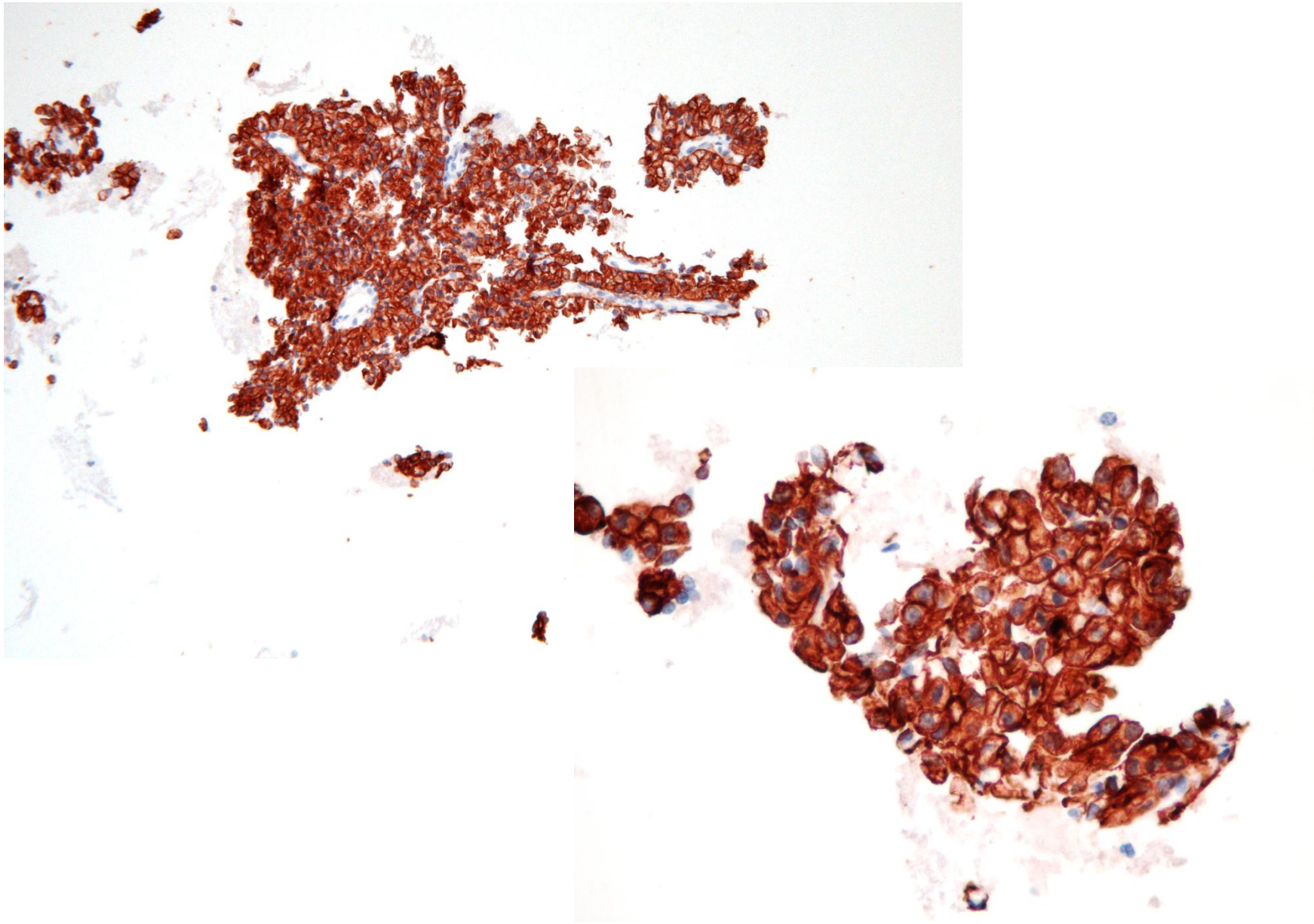

Immunohistochemistry

S-100, vimentin, CK903, PSA, CK7, CD68, CD10:

negative

Cytological diagnosis:

Compatible with a monomorphous adenoma (clear cell or oncocyte type)

Differential diagnosis:

Benign mixed tumor (pleomorphic adenoma)
Myoepithelioma (epithelioid variant)
Oncocytoma
Cystadenoma
Polymorphous low-grade adenocarcinoma
Basal cell adenoma

Parotidectomy – gross examination

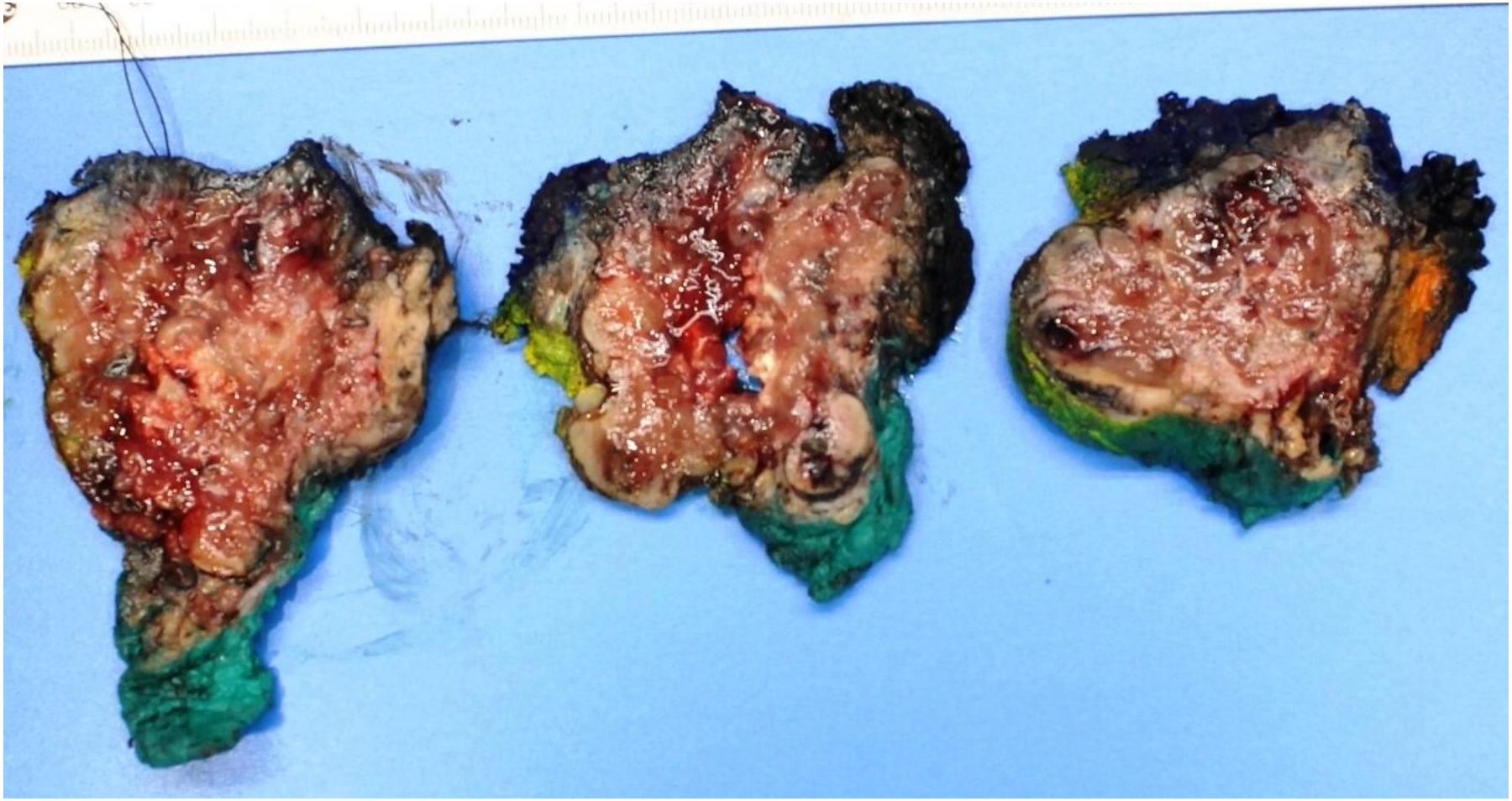

Histology

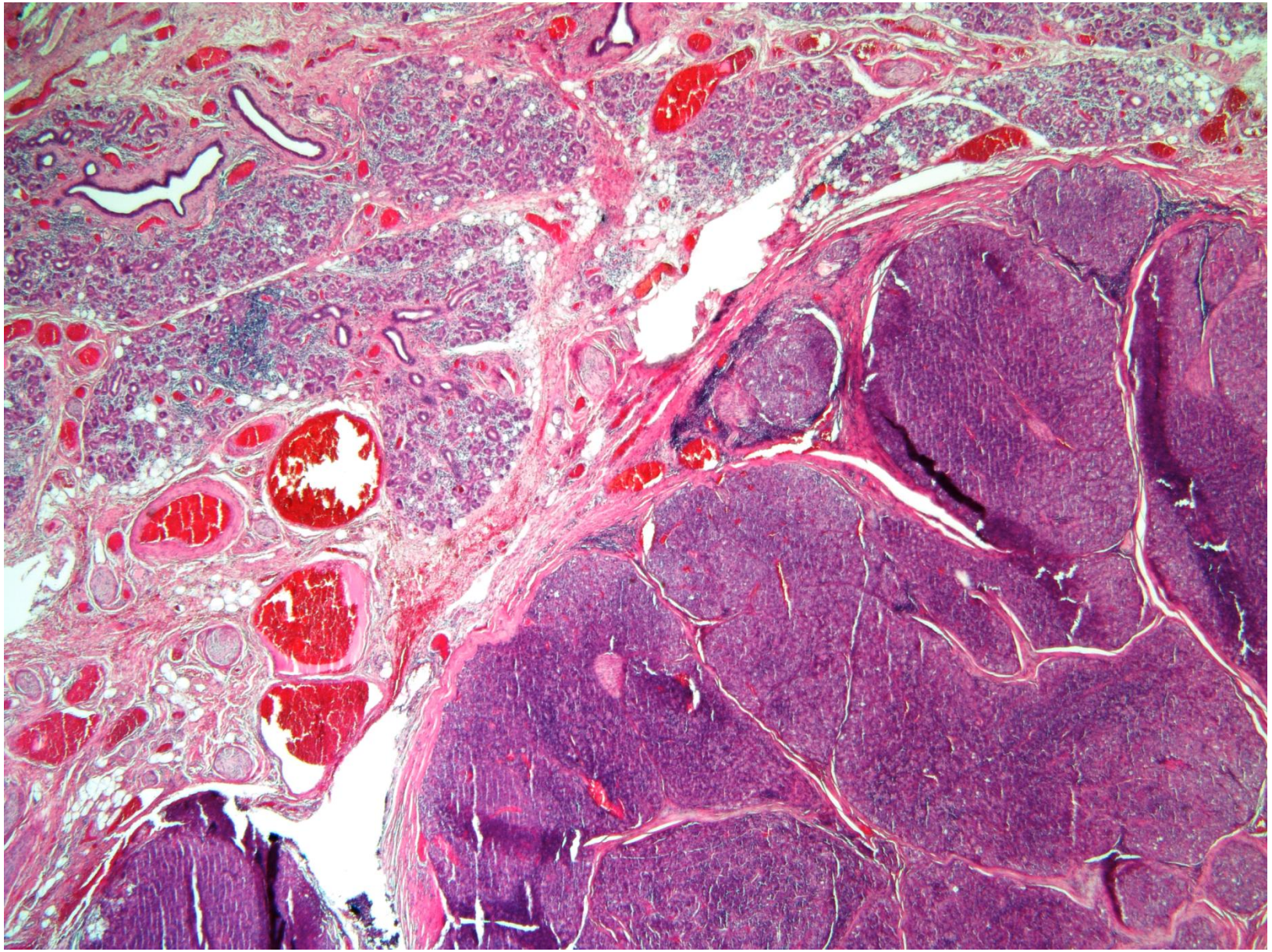

Histology

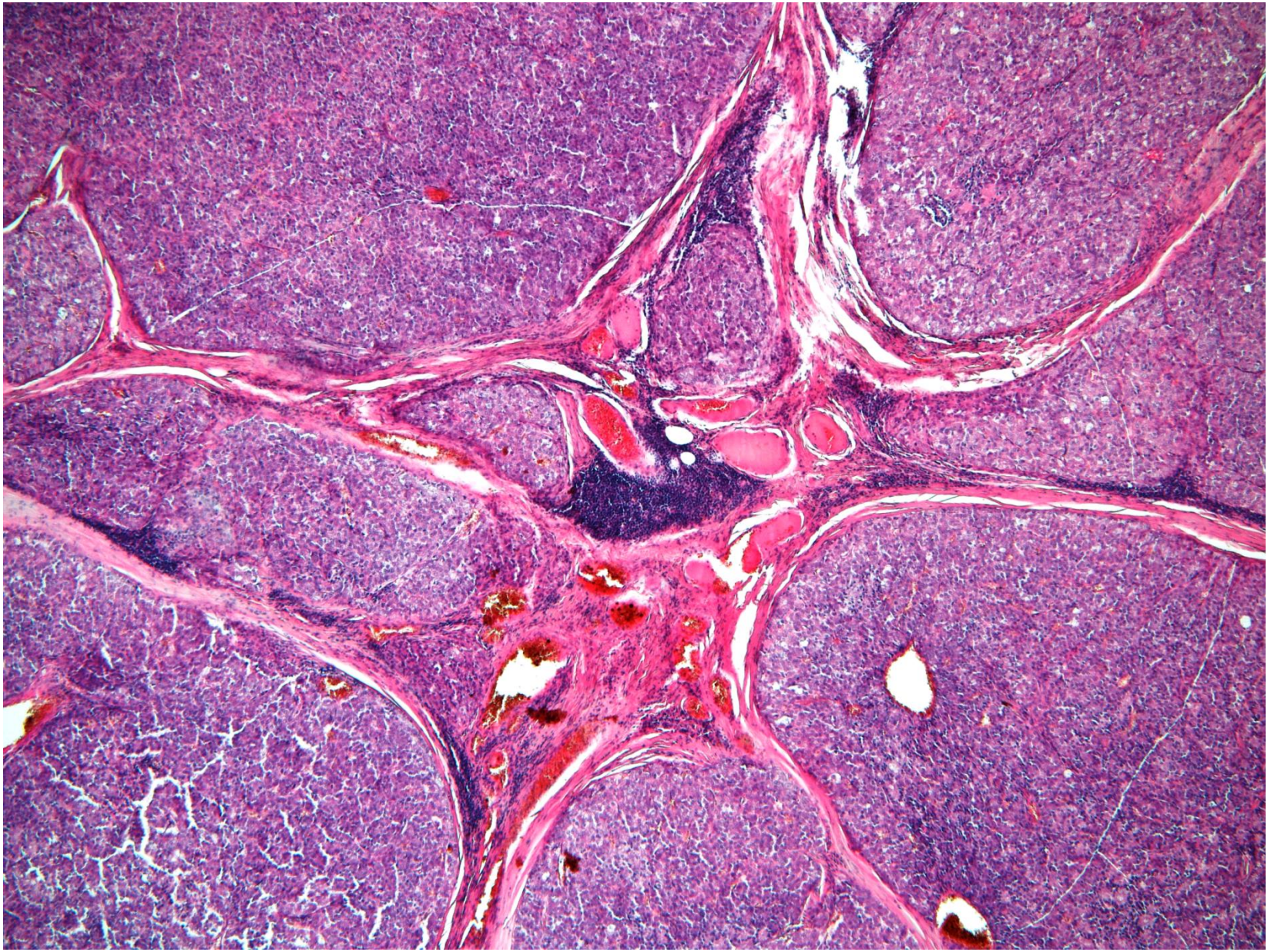

Histology

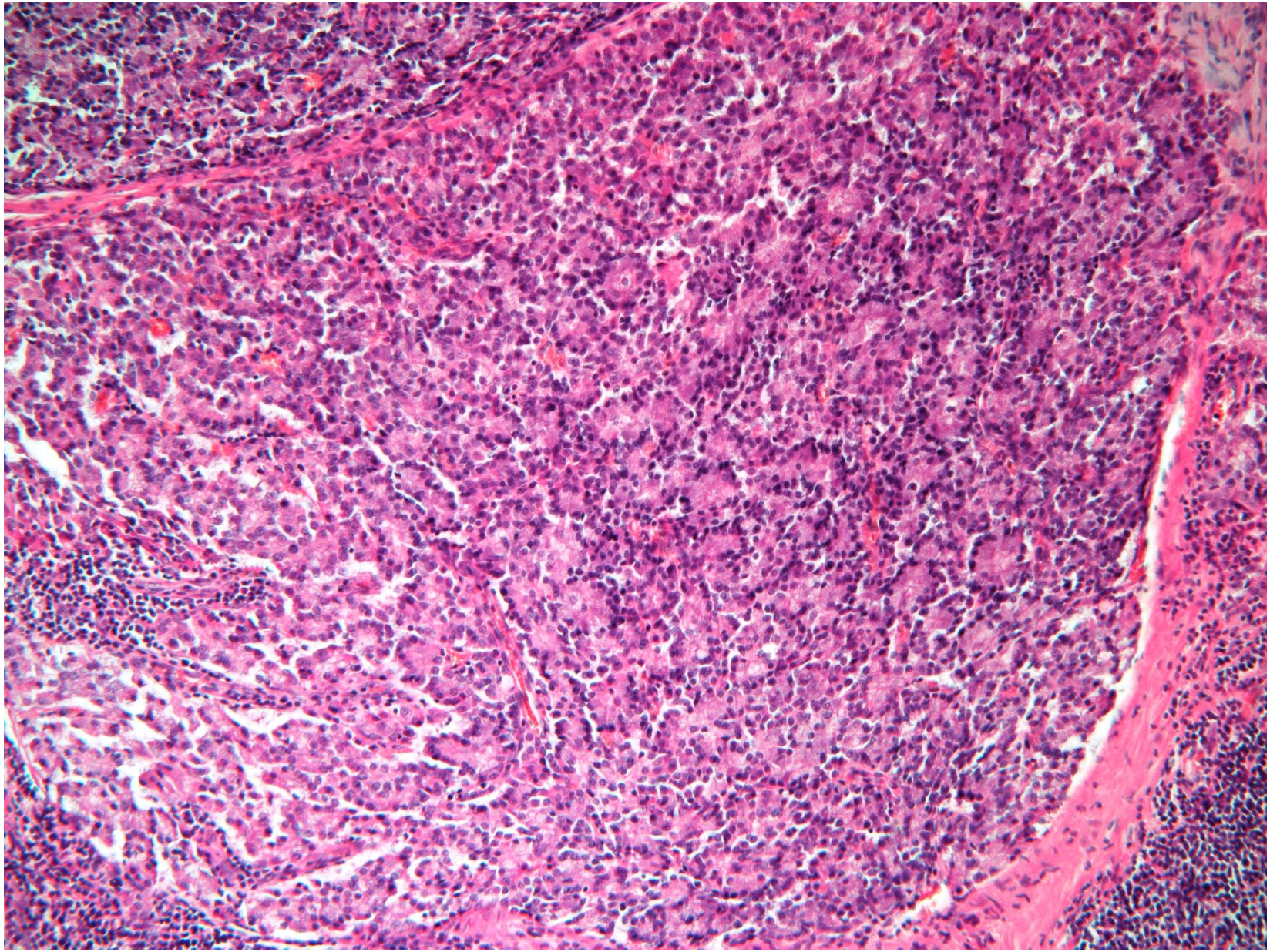

Histology

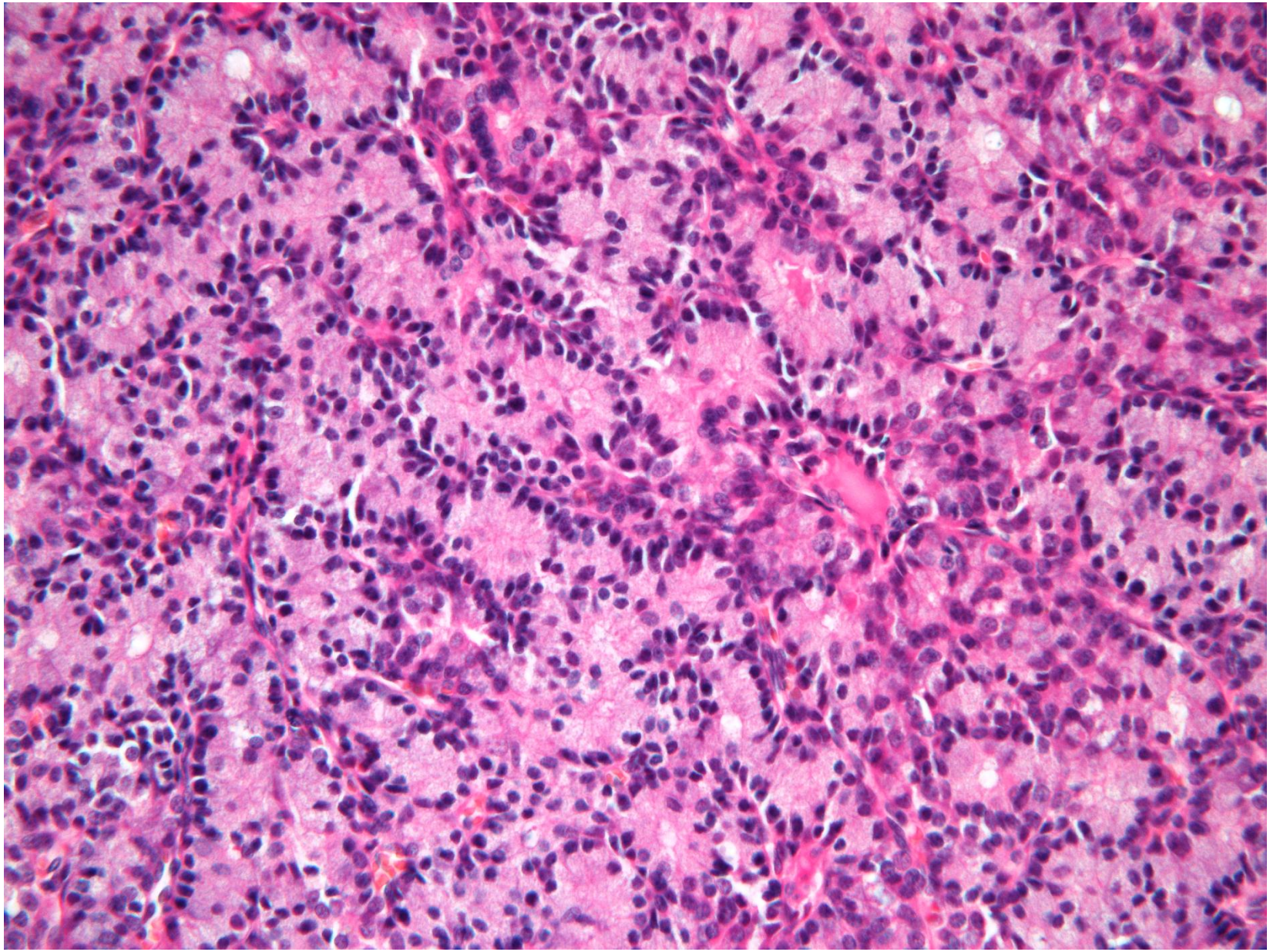

Histology

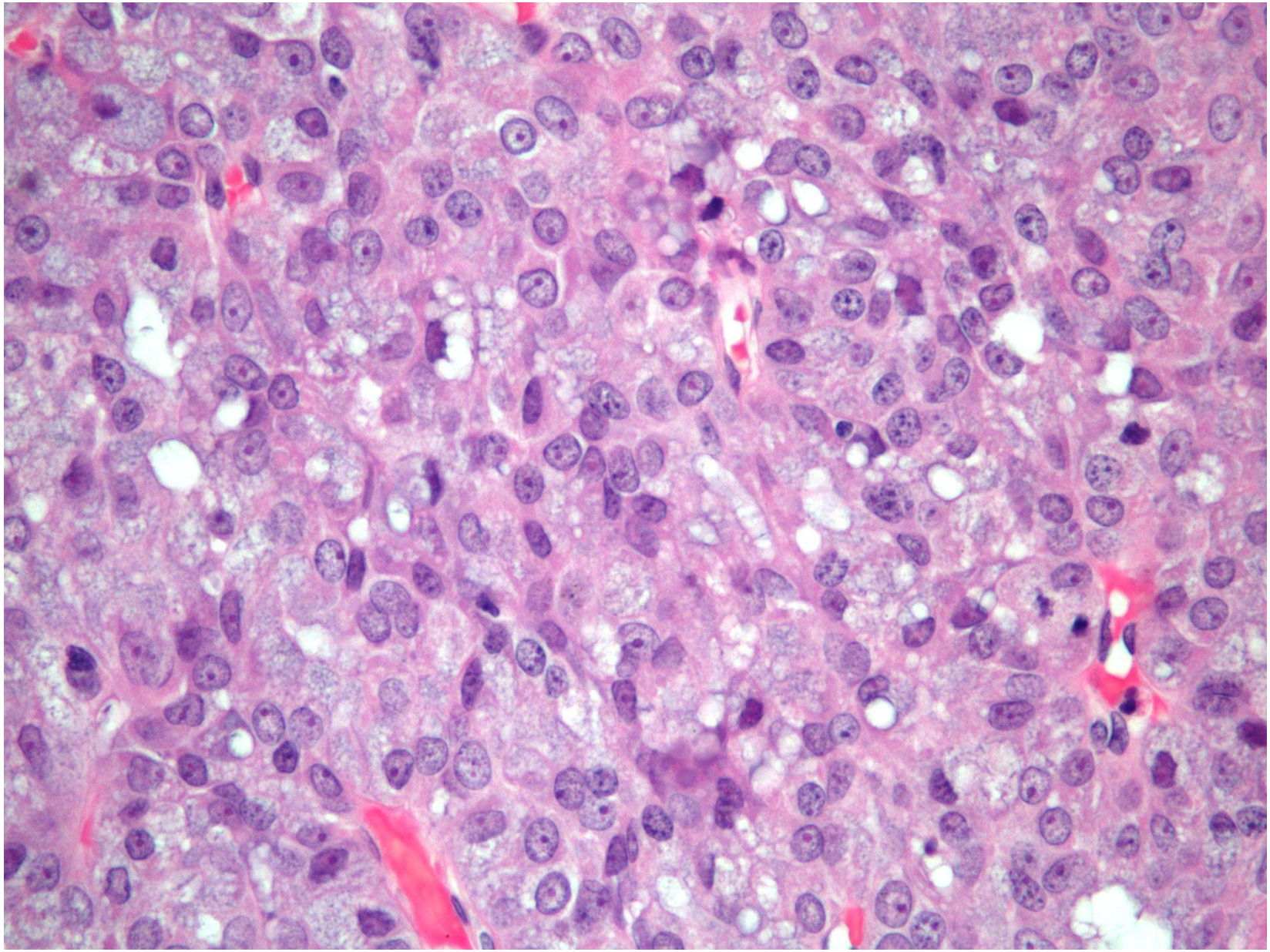

Histology - PAS

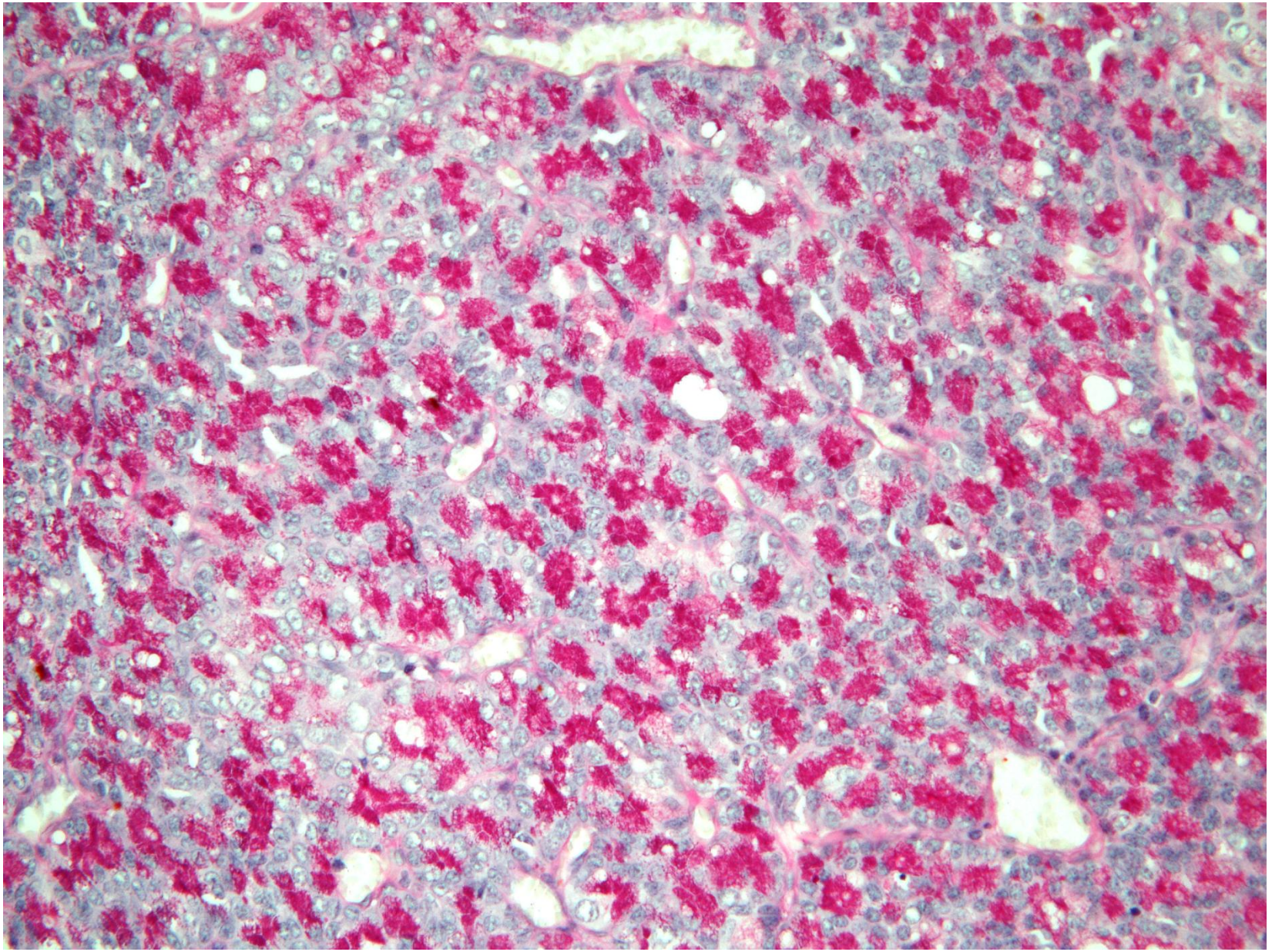

Histology – Diastase-PAS

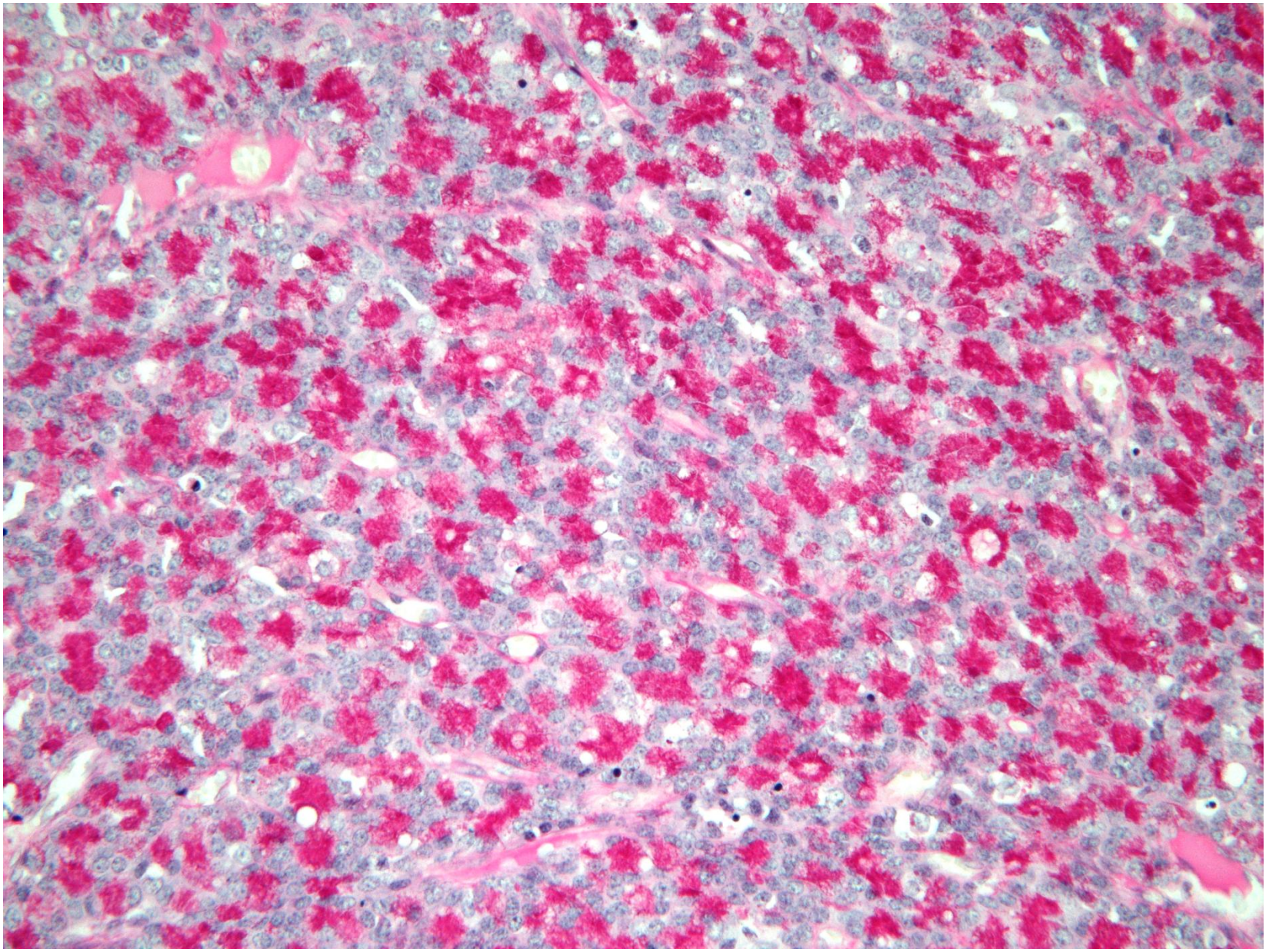

Histology – Alcian blue

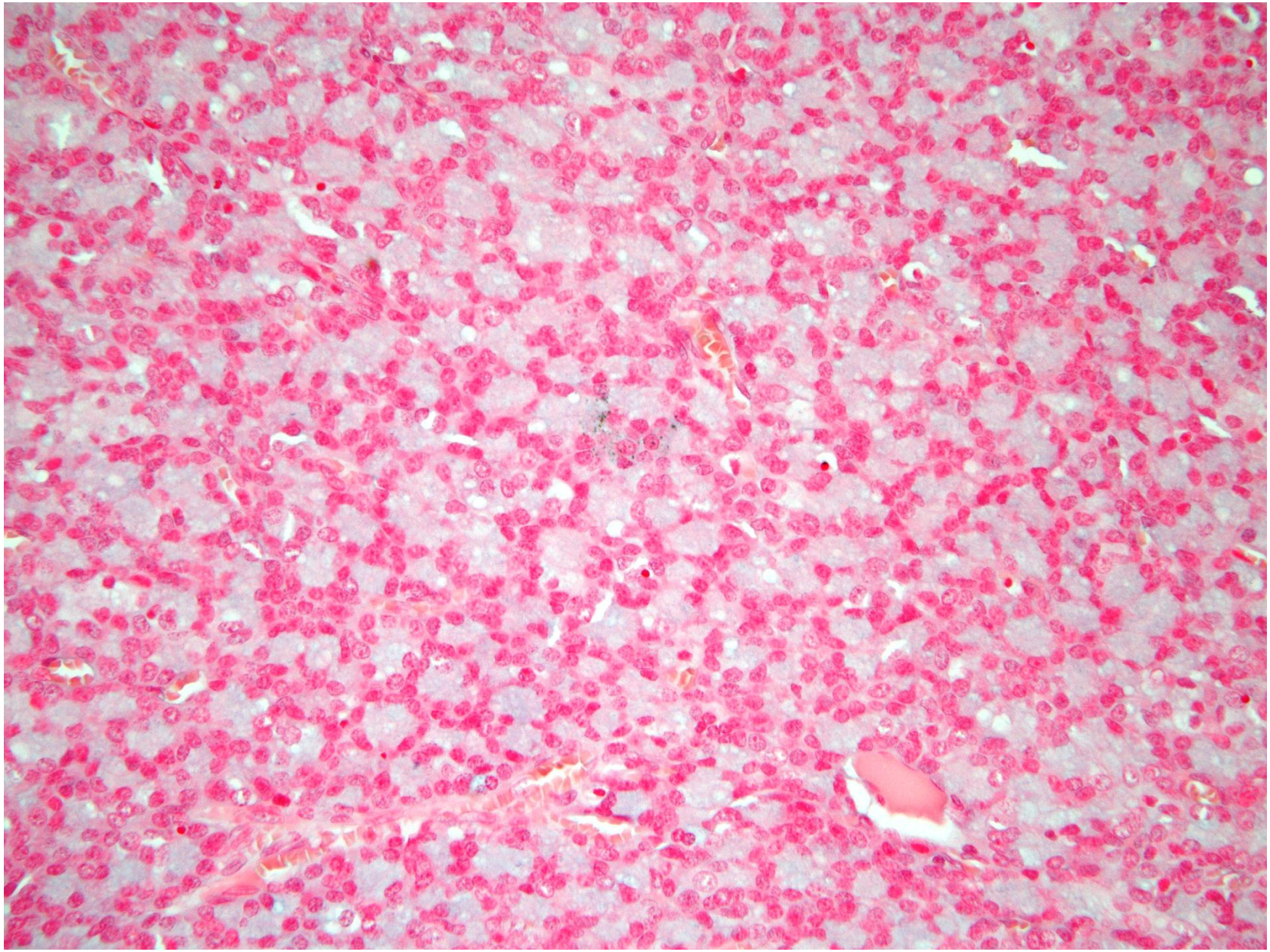

Histological diagnosis:

Acinic cell carcinoma

Take home message:

Usefulness of basic special stains (PAS, D-PAS, Alcian blue) also on cytology in diagnosis of salivary gland tumors